


Human Journals

Research Article


February 2022 Vol.:20, Issue:4

© All rights are reserved by Ahmed Said Abdelhafez et al.

Partial Versus Complete Pulpotomy Using Three Different Materials in Primary Molars: A Clinical Study



IJSRM
INTERNATIONAL JOURNAL OF SCIENCE AND RESEARCH METHODOLOGY
An Official Publication of Human Journals



Ahmed Said Abdelhafez*¹, Abeer Mostafa Abdellatif¹, Hossam Elsherbiny Hamoda¹, Salwa Mohamed Awad²

1 Mansoura, Egypt
2 Damietta, Egypt

Submitted: 22 January 2022
Accepted: 27 January 2022
Published: 28 February 2022



HUMAN JOURNALS

www.ijsrm.humanjournals.com

Keywords: Partial Pulpotomy, Pulpotomy, MTA, Theracal LC, Formocresol

ABSTRACT

Aim of the study: Comparing partial pulpotomy versus complete pulpotomy in primary molars using three different materials clinically and radiographically. **Materials and methods:** It was conducted on sixty molars from thirty children 3 to 6 years. The sample of 60 molars was randomly divided into two groups where group A referred to partial pulpotomy, group B referred to complete pulpotomy. Both techniques were performed for each child using the split-mouth technique. In group A, caries were removed using round bur with removing 2mm of coronal pulp tissues, while in group B, the coronal pulp tissues were completely excavated with a spoon excavator. In both groups, the bleeding was controlled using a moist cotton pellet. Then the medicament was applied according to the grouping randomization process. Accordingly, the children were allocated into 3 subgroups; G1 for Formocresol, G2 for MTA, and G3 for Theracal LC. This is followed by GI filling and SSC. Clinical and radiographic assessments were performed at 6, 9, 12, and 15 months. Statistical analysis was conducted using One-way ANOVA and Chi-square tests. **Results:** Complete pulpotomy showed a higher success rate radiographically and clinically compared to partial pulpotomy without any statistical significance. Meanwhile, MTA showed the highest success rate in comparison to Formocresol and Theracal LC with no detected statistical significance. **Conclusion:** The use of complete pulpotomy tends to be superior over partial pulpotomy, however, the partial pulpotomy technique could be used as an alternative with acceptable results. MTA seems to be more successful compared to other materials.

INTRODUCTION

Aim

This study was conducted to compare partial pulpotomy versus complete pulpotomy in primary molars using three different materials clinically and radiographically.

Review of Literature

For decades, there has been a search for the best (safe and effective) ways of managing pulpal disease due to caries and traumatic pulpal exposure. These efforts have generated different materials and methods trying to reach the most convenient technique. (1) Primary teeth play an important role in mastication, phonetics (speech), esthetics and also act as a space maintainer for permanent teeth. The most important objective of pediatric dentistry treatment is the preservation of functional primary teeth until natural exfoliation through early and well-indicated pulp therapies. (2, 3) One of the main reasons that are responsible for the premature loss of primary teeth is dental caries. (4)

Challenges regarding the best treatment option in primary molars with deep carious lesions that are free of signs or symptoms have continued over the years. Indirect pulp therapy (IPT), direct pulp cap (DPC), and pulpotomy are all viable options for treating the pulp in primary teeth with deep carious lesions according to a recent systematic review and a new American Academy of Pediatric Dentistry (AAPD) Guideline for vital pulp therapy. (5, 6) Partial Pulpotomy (PP) as a type of vital pulp therapy also indicated as in young permanent teeth at which pulp exposure occurs due to caries and the bleeding site can be controlled easily within minutes. (7)

Pulpotomy is a vital pulp therapy for deciduous teeth in which part of the coronal pulp tissue is surgically removed and a suitable material is placed on the remaining radicular pulp to protect it from further injury. (8, 9) A pulpotomy is performed in a primary tooth with extensive caries but without evidence of radicular pathology when caries removal results in a carious or mechanical pulp exposure. Pulpotomy aims to retain a functional tooth with a vital radicular pulp in the oral cavity until its exfoliation. (10)

Pulpotomy is one of the most widely accepted clinical procedures for treating deep carious lesions with exposed pulps in symptom-free primary teeth. The rationale is based on the healing

ability of the radicular pulp tissue following surgical amputation of the affected or infected coronal pulp. (11) It can be performed using different techniques including non-pharmacotherapeutic treatments such as electrosurgery (ES) and laser or pharmacotherapeutic approaches by dressing the pulp tissue with different medicaments or biological materials such as Formocresol (FC), glutaraldehyde (GA), ferric sulfate (FS), Calcium Hydroxide $\text{Ca}(\text{OH})_2$, MTA, Calcium-enriched mixture (CEM) cement, sodium hypochlorite (NaOCl). (11) Other materials have been also evaluated for pulp cappings such as Biodentin, and Theracal. (12)

Pulpotomy is a minimally invasive procedure whereby the inflamed/diseased pulp tissue is removed from the coronal pulp chamber of the tooth leaving healthy pulp tissue which is dressed with a dental biomaterial that maintains pulpal vitality and promotes repair. (13) The procedure can either be partial (whereby 2–3 mm of the coronal pulp is removed) or complete pulpotomy (in which the entire coronal pulp is removed). (14)

The objective of complete pulpotomy treatment is to remove coronal inflammatory tissues, which usually contain microorganisms; therefore, healing is allowed to take place at the entrance of the root canal with essentially healthy pulp tissue. (15) Although dilute formocresol (1:5 Buckley's solution) has long been regarded as the gold standard for wound dressing of pulpotomies primary teeth, other agents can also protect the radicular pulp, promoting healing and providing good treatment outcomes. The use of formocresol has been questioned because of its adverse effects, such as potential carcinogenicity, mutagenicity, and cytotoxicity. Moreover, the major component of formocresol, formaldehyde, might be distributed systemically after pulpotomies. (16)

Under such circumstances, a partial pulpotomy (PP) should simplify pulpal treatment compared to a complete pulpotomy. In 1982, Cvek introduced this technique for permanent traumatized teeth with a complicated crown fracture to preserve the remaining pulp tissue, which involved removing 2mm of pulp and then dressing the non-inflamed pulp with calcium hydroxide $\text{Ca}(\text{OH})_2$. (17) PP is also indicated in young permanent teeth with a carious pulp exposure in which pulpal bleeding can be controlled within several minutes. (18) In PP, no sizable vessels are cut, making it easier to control the bleeding and consequently avoid a blood clot between the wound surface and dressing material. (19) Lower surgical trauma and shorter surgical time are the other advantages of PP. Partial Pulpotomy also requires a limited occlusal access opening;

therefore, a more conservative restoration such as composite resin may reduce the need for aggressive tooth preparation. (17, 20)

Modern pediatric dentistry seeks novel materials that allow the regeneration of the remaining dental tissues. MTA, developed in the 1990s,(21) is a bioactive silica cement, mainly comprised of calcium and silicate elements, used for cervical pulpotomies in primary teeth(22, 23); it presents biocompatibility, satisfactory sealing ability, and capacity for stimulating the repair process. The purpose of this randomized controlled trial (RCT) study was to evaluate: the clinical and radiographic success rates of partial pulpotomy compared with pulpotomy using three different materials.

The objective of the research

To help in building an evidence-based decision for treating primary molars with partial pulpotomy technique.

MATERIALS AND METHODS

Study design

The study design was a parallel randomized, split-mouth, clinical trial conducted according to the Consolidated Standards of Reporting Trials (CONSORT) guidelines. (24) This study was approved by the Ethical Committee of the Faculty of Dentistry, Mansoura University with code no (M15120219). This research was performed at the University's Department of Pediatric Dentistry between February 2019 and October 2021 under clinicaltrials.gov ID no. NCT05190783.

Methodology

A total of sixty restorable second primary molars in thirty healthy children with deep carious lesions were pulpotomies for this study. The clinical inclusion criteria were as follows: no history of spontaneous or nocturnal pain, no tenderness to percussion or palpation, no swelling, no mobility, no sinus draining fistulas, teeth with no pulp exposure after caries removal, and no pulpal bleeding that could not be controlled after amputating 2mm of pulp tissues, the absence of external or internal root resorption, no widening of the periodontal ligament space, and no apical

or furcation radiolucencies, as determined by radiography, were adopted as radiographic inclusion criteria. Before starting treatment, the probable risks and benefits were explained to parents, and written informed consent for treatment was obtained.

Randomization and grouping

The sample size was estimated based on the previous literature findings and by consulting a biostatistician. Before treatment, a random sequence generation procedure was performed using the website www.randomizer.org to obtain a series of randomized real numbers corresponding to cases one to 30. The total sample of 60 molars was equally and randomly divided into two main groups where group A referred to partial pulpotomy while group B referred to complete pulpotomy. Both techniques were performed for each child using the split-mouth technique where each group included 30 molars. Within each main group (A&B), three different materials were used including Formocresol (A1, B1), MTA (A2, B2), and Theracal LC (A3, B3), where each subgroup included 10 molars. Patients with an even number were allocated to scheme one, while patients with an odd number were allocated to scheme two. Scheme one involved treating right molars with partial pulpotomy and treating left molars with a complete pulpotomy. In scheme two, the reverse protocol was applied. The participants and parents were blinded to the materials used and the methods applied.

Clinical Steps

All treatment procedures were performed using non-pharmacologic behavior guidance techniques. A pre-operative digital x-ray was taken before treatment to be as a reference compared with the post-operative one. Study participants received local anesthesia (Articaine, septodont) then rubber dam isolation was utilized for all teeth in both groups.

(Partial Pulpotomy; PP) Group A:

The pp procedure included the complete removal of caries till exposure occurred. The exposed surface of the pulp was gently removed using a sterile round diamond bur (Drendel and Zweiling Diamant GmbH, Lemgo, Germany) and a high-speed, water-cooled handpiece with light hand pressure. The removal of the pulp did not exceed approximately 2mm. To control bleeding, a

moist sterile cotton pellet was applied over the site with gentle pressure; hemostasis was successfully achieved in all cases. (7)

According to materials that were used the following groups were categorized as follows: In group A₁, the exposure site was treated with a cotton pellet dampened with 1:5 dilutions of formocresol (PERVEST, DenPro, India) for up to 4 minutes. The exposure site was covered with zinc oxide and eugenol paste (PREVEST, DenPro, India) for hermetic sealing. In group A₂, the exposure site was treated with MTA (MTA-Angelus, Londrina, Paran, Brazil) paste which was mixed, according to the manufacturer's directions, at a three-to-one ratio of MTA powder and sterile water then was placed on the exposure site. Next, a sterile moistened cotton pellet was applied to the paste with gentle pressure. While in group A₃, Theracal LC (BISCO Dental, SCHAUMBURG, IL, USA) was applied on the exposure site. All molars were filled with GI (Midfil, PROMEDICA, Neumunster, Germany) followed by coverage with prefabricated stainless steel crowns (3M ESPE, USA) that cemented with glass ionomer cement (GC Gold, Tokyo, Japan).

(Complete Pulpotomy) Group B:

This procedure included removal of the carious tooth structure and de-roofing of the pulp chamber with a round carbide bur with high speed and water spray. The coronal pulp tissues were removed using a #4 carbide bur with slow speed and a sharp spoon excavator. The pulp chamber was irrigated with saline and hemostasis of the amputation site was obtained with a water-dampened cotton pellet. (7)

The following groups were categorized as follow: In group B₁, where Formocresol (PERVEST DenPro, India) was used, while in group B₂, MTA (MTA-Angelus, Londrina, Paran, Brazil) was used and in group B₃, Theracal LC (BISCO Dental, USA) was applied. All materials of group B were applied in the same manner as in group A.

At the end of 6, 9, 12, and 15 months, all teeth were evaluated clinically and radiographically based on AAPD criteria. Clinical evaluation included four criteria; pain, fistula, tenderness, and abnormal mobility while radiographic evaluation included five criteria; radiolucency (periapical-radicular), resorption (internal-external), widening in the periodontal ligament, pulp canal obliteration (PCO), and permanent crypt involvement.

Statistical analysis

The Data were gathered and statistically analyzed. Agreement and reliability were calculated as kappa agreement (95% CI). One-way ANOVA test and Chi-Square test were used for the analysis of demographic data while Chi-Square test was used for the analysis of radiographic and clinical data.

RESULTS

The Inter-examiner reliability test, which was assessed in 10 patients examined by two different examiners, was k equals 0.756 which was a substantial agreement. Intra-examiner reliability, which was assessed in 10 patients examined on two occasions over a one-week interval, was k equals 0.988 which was a perfect agreement.

Sixty-five children were screened and 30 (17 boys and 13 girls) met the inclusion criteria. At the time of treatment, the patient's ages ranged from 3 to 6 years old with the mean age of the studied groups being 5 years. Since the split-mouth method was used in this trial, no differences were detected between the two groups in terms of gender distribution and age.

At 6 and 9 months follow up

Clinical assessment revealed 100 % success in all subgroups, meanwhile, the radiographic assessment showed one molar with furcation radiolucency in group A₁ with a 90% success rate at 9 months.

At 12 months follow up

Clinically, one molar revealed sensitivity to percussion in group A₁, whilst no clinical failure was observed in both groups of MTA or Theracal. Radiographically, in the A₁ subgroup, three molars demonstrated failure due to radiolucency in three of them and widening in a periodontal ligament in one of them, whilst the B₁ subgroup, three failures were detected; furcation radiolucency in all of them while two of them showed widening in the periodontal ligament. In the A₂ subgroup, one molar revealed radiolucency, while in the B₂ subgroup, no radiographic failure has been monitored. Finally, A₃ subgroup, two molars showed radiolucency in the furcation area, while B₃ showed no failure at this period.

At 15 months follow up

Clinically, in group A₁, two molars showed pain with percussion and one of these molars showed mobility as well, while in group B₁ three clinical failures were detected; three molars showed tenderness and two of them showed abnormal mobility as well. In the A₂ subgroup, two clinical failures pain were found; pain with percussion and mobility, while in the B₂ group only one clinical failure was found; pain with tenderness. In the A₃ group, only two molars showed pain on percussion while only one molar was detected in the B₃ group with pain, tenderness, and abnormal mobility.

Radiographically, furcation radiolucency, as well as a widened periodontal ligament space, were reported in two molars in the A₁ subgroup. On the other hand, in the B₂ subgroup two molars demonstrated radiolucency, widening in periodontal ligament and crypt involvement. In the A₂ subgroup, one molar revealed radiolucency and widening in periodontal ligament while another one showed radiolucency with widening in periodontal ligament and crypt involvement with root resorption. On the other hand, in the B₂ subgroup, only one molar revealed radiolucency, resorption, and widening in the periodontal ligament. In the A₃ subgroup, one radiographic failure was detected due to radiolucency in the furcation region, while in the B₃ subgroup only one molar showed failure due to radiolucency, resorption, and widening in periodontal ligament space. However, another molar showed only widening in periodontal ligament space, it was not considered as a failure.

So, after 12 months of follow-up, the clinical and radiographic success rates of subgroup A₁ were 90 % and 78%, respectively, while the success rates for the A₂ subgroup were 100% clinically, 90% radiographically and regarding the A₃ subgroup 100% clinically and 80% radiographically. While at 15 months follow up, the clinical and radiographic success rates of the A₁ subgroup decreased to 78% and 85%, respectively, while in B₁, 70 % clinical and 100% radiographic success was detected for the remaining cases. In the A₂ subgroup, 80% of cases showed success clinically and radiographically, while the B₂ subgroup showed 90% clinical and radiographic success. Finally, for the A₃ subgroup, 80% success rate was detected clinically and 87.5% was detected radiographically, while 90% success rates were clinically and radiographically for the B₃ subgroup. So, the overall success rate in all four periods of follow-up was 60% for the A₁

subgroup and 70% for the B₁ subgroup, 80% and 90% for subgroups A₂ and B₂, respectively, and 70% for subgroup A₃ and 80% for subgroup B₃.



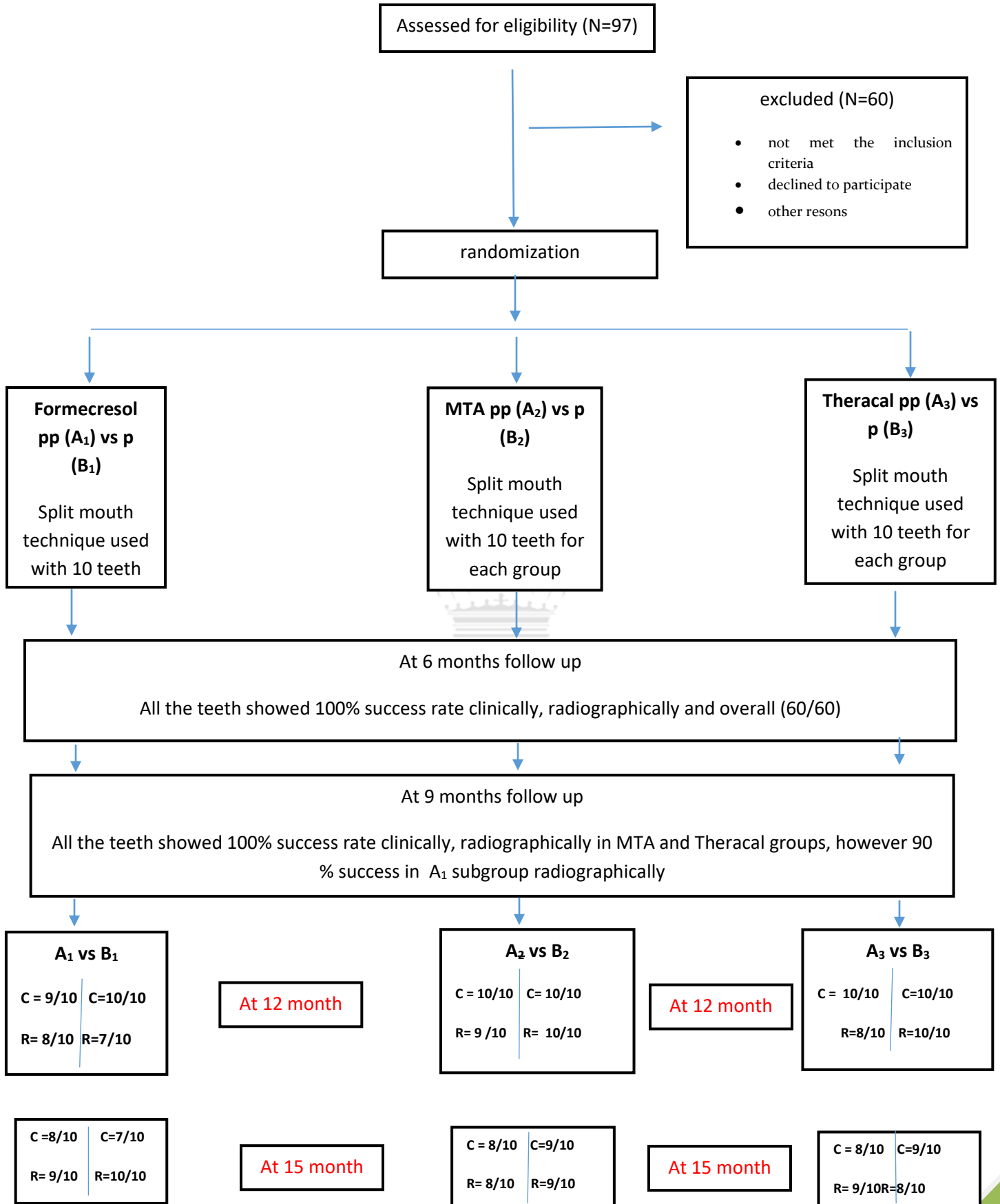


Table (1): shows that there was a statistically significant difference between studied groups for the presence of radiolucency at 12 months with 30% of the samples among the B₁ subgroup. All other radiographic findings illustrated the non-statistical significant difference between groups. The success rate at 12 months showed a statistically significant difference between groups with the lowest success rate was detected among the B₁ subgroup 70% versus 100% among B₂ and B₃ subgroups.

Table (1): comparison of radiographic evaluation Criteria between studied groups with a pulpotomy

Radiographic evaluation Criteria	period of assessment	Pulpotomy			Chi-Square test, P-value
		Formocresol B ₁	MTA B ₂	Theracal B ₃	
		n=10(%)	n=10(%)	n=10(%)	
Radiolucency	12	3(30.0)	0	0	0.036*
	15	3(30)	1(10)	1(10)	0.383
Resorption	12	0	0	0	...
	15	2(20)	1(10)	1(10)	0.749
Widening PL	12	2(20)	0	0	0.117
	15	3(30.0)	1(10)	2(20)	0.535
Success	12	7(70.0)	10(100)	10(100)	0.036*
	15	7(70.0)	9(90)	8(80)	0.535

Table (2): Comparing studied groups among partial pulpotomy; showed no statistically significant difference between studied groups for the presence of clinical findings at all follow-up periods from 6 to 15 months. The success rate at 6 and 9 months was the same for all studied groups (100% each). The success rate at 12 months was 90% for the A₁ subgroup versus 100% for other subgroups and at 15 months was 80% for A₂ and A₃ subgroups with the least are detected for the Formacresol subgroup 70% without statistically significant difference between them. At 6 and 9 months follow up the three groups of partial pulpotomy showed no signs of clinical failure.

Table (2): comparison of clinical evaluation criteria between studied groups with a partial pulpotomy.

Clinical evaluation Criteria	period of assessment	Partial pulpotomy			Chi-Square test, P value
		Formocresol A ₁	MTA A ₂	Theracal A ₃	
		n=10(%)	n=10(%)	n=10(%)	
Pain	12	1(10)	0	0	0.355
	15	0	1(10)	1(10)	0.585
Tenderness	12	1(10)	0	0	0.355
	15	3(30)	2(20)	2(20)	0.830
Fistula	12	0	0	0
	15	1(10)	0	1(10)	0.585
Mobility	12	0	0	0
	15	1(10)	2(20)	1(10)	0.749
Success	12	9(90)	10(100)	10(100)	0.355
	15	7(70)	8(80)	8(80)	0.830

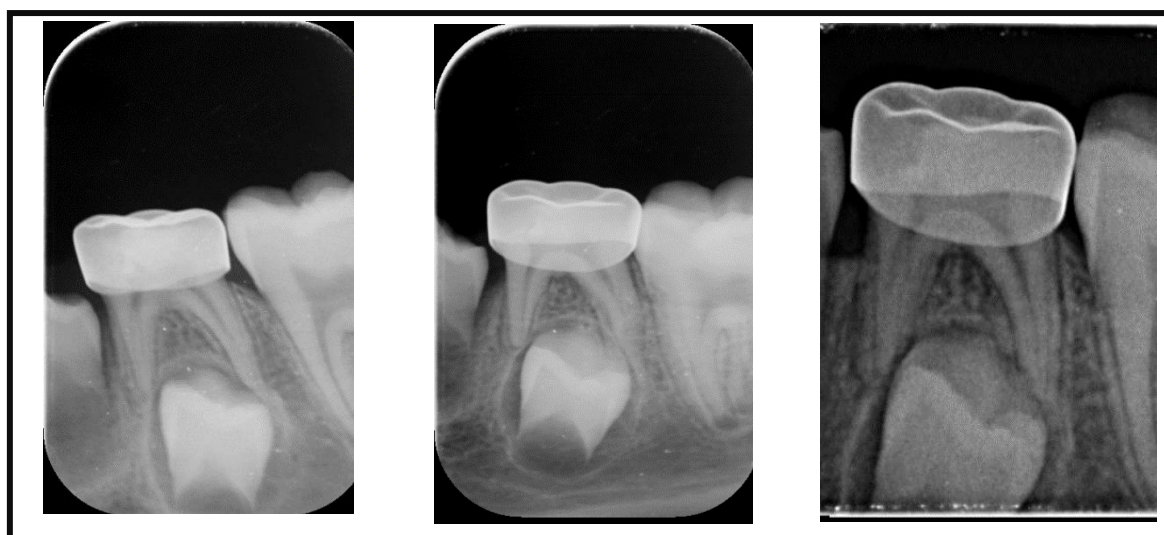


Fig. 1 partial pulpotomy with theracal after 9, 12, and 15 months follow up

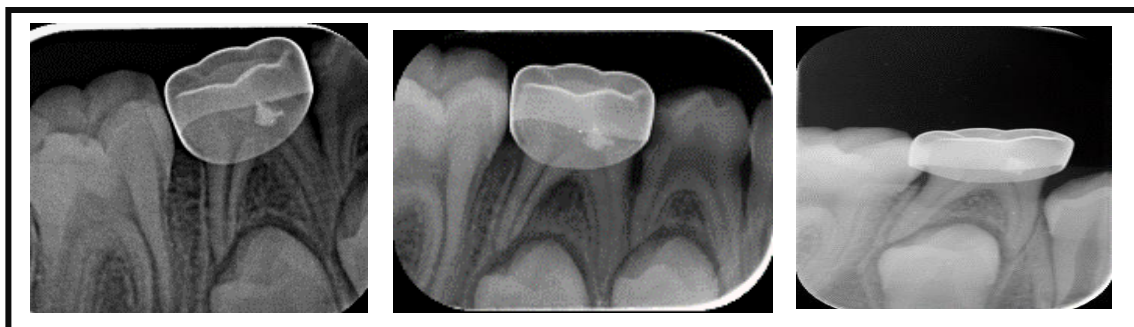


Fig. 2 partial pulpotomy with MTA after 9, 12, and 15 months follow up

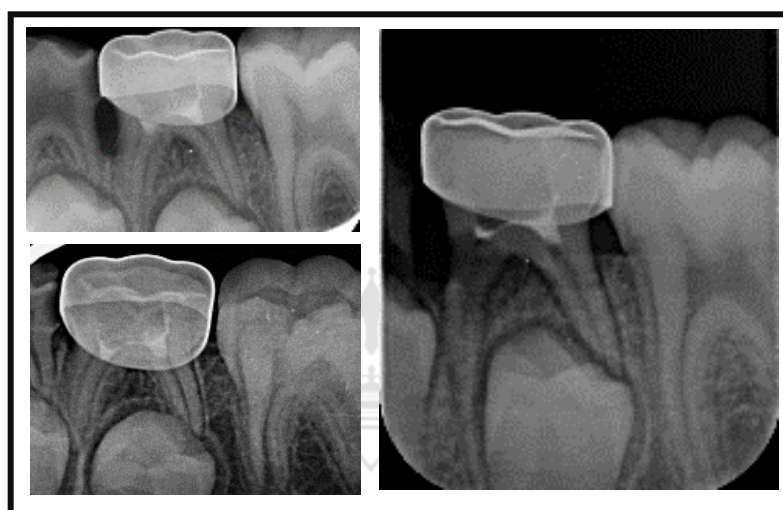


Fig 3. Pulpotomy with MTA after 9,12 and 15 months follow up

DISCUSSION

Preservation of an intact primary dentition till the eruption of their permanent successors is the key for maintaining the arch form. In this study pulpotomy and partial pulpotomy were performed to preserve the vitality of primary teeth that have suffered pulpal insult from dental caries. Therefore, aiding in the prevention of tongue habits, prevention of possible speech problems, and maintaining masticatory function. Preserving pulp vitality and the pulp-dentin complex seems to help in a more conservative procedure that should be part of our main goal in modern dentistry. (5, 6, 11)

The selected age for this study was ranged from three to six years old in accordance with other studies. This age was selected as caries is common at this age. In addition, to ensure a sufficient

amount of root length of the selected primary molars that are indicated for pulpotomy and to avoid normal physiologic root resorption. In this study second primary molars were selected for standardization and for the high prevalence of dental caries in this tooth and to ensure that radiographic evidence of all pathology would be detected without the overlapping of the roots and underlying permanent teeth. Teeth that did not show any sign of pulp exposure after removal of caries or bleeding could not be controlled after amputation of 2mm of pulp tissue were excluded from this study as it showed a sign of irreversible pulpitis which is not indicated for vital pulp therapy within the study. The partial Pulpotomy technique was selected as it has several advantages; it causes limited injury to the pulp and limited loss of tooth substances, and this is important for pulpal healing and easier restoration. All teeth were covered with SSC restoration as it has been reported to have a good survival rate in primary carious molars and considered as the ideal option in the restoration of primary teeth treated with vital pulp therapy. (20, 25)

Although many studies suggested that Formocresol in humans could have toxic and carcinogenic effects, Formocresol pulpotomy continues to be the most preferred treatment choice for treating carious primary molars. Therefore, it was chosen to be the control treatment in this study, (26) however, it is still important to search for an alternative material to Formocresol to replace it with other techniques. There are many different materials that have been used in complete pulpotomy of asymptomatic primary molars with deep carious lesions such as ferric sulfate, laser, electrosurgery, and MTA. (5, 21, 27) Several studies, systematic reviews and meta-analyses reported significantly greater or similar clinical and radiographic success rates for MTA compared with Formocresol as a pulpotomy agent in primary molars. (28) MTA has also been shown to be a reliable pulp dressing material in a DPC and partial pulpotomy of permanent teeth. (21, 29) Using MTA as a biocompatible, bioactive, non-cytotoxic, and antibacterial material for the vital pulp therapy in primary molar with a deep carious lesion may promote an environment that is more favorable for reparative dentin formation and regeneration in reversibly inflamed pulps. (21) Theracal LC was chosen to be the interventional treatment in this study as there were only a few studies published that investigated the clinical performance of Theracal as a vital pulp therapy agent in primary teeth.

The present study results demonstrated that MTA was a superior pulpotomy agent in primary teeth than Formocresol and Theracal LC. Regarding the overall success rate, MTA pulpotomy showed a 90% success rate and Formocresol demonstrated a 70% success rate and Theracal LC illustrated 80%. Comparing MTA pulpotomy group to Formocresol Pulpotomy group, the overall success results of MTA were higher than Formocresol group and this comes in accordance with other results; Farsi and colleagues (2005)(30), Ubramaniam and colleagues (2009) (31), and ushynski and colleagues (2012). (23) On the other hand, Noorollahian (2008) (32) and Fernandez and Colleagues (2013)(33) reported less favorable results of MTA. This could be explained that procedures were performed by multiple operators might have increased the heterogeneity of the results and also may be due to the absence of standardization.

Comparing Theracal pulpotomy group to Formocresol pulpotomy group, the results were in accordance with other studies, Petrolo F et al (2014)(34), and Erfanparast L et al (2018)(35), who used Theracal as a direct pulp capping agent and their results were 93,3 % after 2 years follow up and 91.8 % at the end of one year follow up periods, respectively. The results of this study were in accordance with Sahar M et al (2019)(36) with an 88.9% success rate and Abdullah H et al (2020)(37) with a radiographic success at 12 months follow up 90% who used Theracal as a pulpotomy agent. On the other hand, Lee H et al (2015)(38) reported less favorable results of Theracal. This could be explained on the basis of differences in the histologic nature of the pulp of dogs. Also, maybe due to using glass ionomer as the final restoration.

The overall success rate of Partial Pulpotomy with MTA, which was 100 percent, 100 percent, 90 percent, and 80 percent at 6,9,12 and 15-month follow-up, respectively, which come in accordance with Nematollahi H et al (2018)(7) which scored 100 % and 95 % success rate at 6 and 12 months follow up respectively and was higher or similar compared to those of PP with CH at the same follow-up period in the studies conducted by Trairatvorakul and Koothiratrakarn (2012)(20) and was higher compared to those of PP with CH at 12 months in a study conducted by Schroder et al.(19) The use of MTA as a bioactive dressing material in this study may modulate the pro-inflammatory cytokines, like IL-1 α , IL-6, and IL-8, in the coronal pulp of the teeth with deep carious lesions, reducing the chances of failure (39); this may help explain the success rate of PP with MTA. The design of this study, involving the exclusion of the samples where bleeding could not be controlled after amputating 2mm of pulpal tissue, was similar to that

of the studies conducted by Trairatvorakul and Koothiratrakarn (2012)(20); however, it had not been considered in the study conducted by Schroder et al.,(19) which can help explain the higher failure rate in their study. In the group involving PP with MTA in the present study, an SSC was implemented as a restoration; however, in the study by Schroder et al, amalgam filling restoration was done.

The overall success rate of partial pulpotomy with Formocresol was 60% over a 15-month period follow up. Unlike the result of Mariam Anwari et al (2020)(40) who compared partial pulpotomy with formocresol versus honey, the formocresol success rate was 97 % on the 7th day and 85.7 % on the 60th day. This could be explained that this study follow-up period was only for 60 days while the present first period of follow-up was after 6 months.

CONCLUSION

Based on this study's results, the following conclusions can be made:

The use of complete pulpotomy tends to be superior over partial pulpotomy, however, the partial pulpotomy technique could be used as an alternative with acceptable results. MTA seems to be more successful compared to formocresol and Thercal LC. Even so, TheraCal LC can be regarded as a biocompatible alternative to formocresol when a cheaper and easier technique than MTA is preferred. Moreover, longer-term evaluations may be needed to assess the possible late effects of monomers in TheraCal LC on treatment outcomes. The authors deny any conflicts of interest related to this study.

ACKNOWLEDGMENT

This study was supported by Mansoura University, Faculty of Dentistry. Special thanks to the staff at the Department of Pediatric Dentistry, the children, and parents for their participation in this study.

REFERENCES

1. McDonald RE. [Treatment of deep caries, of exposure of vital pulp and of pulpless teeth in children]. Boletin de la Asociacion Argentina de Odontologia para Ninos. 1965;7(1):14-7 contd.
2. Guideline on Management of the Developing Dentition and Occlusion in Pediatric Dentistry. *Pediatr Dent*. 2016;38(6):289-301.
3. Northway WM. The not-so-harmless maxillary primary first molar extraction. *J Am Dent Assoc*. 2000;131(12):1711-20.
4. Finucane D. Rationale for restoration of carious primary teeth: a review. *Eur Arch Paediatr Dent*. 2012;13(6):281-92.
5. Coll JA, Seale NS, Vargas K, Marghalani AA, Al Shamali S, Graham L. Primary Tooth Vital Pulp Therapy: A Systematic Review and Meta-analysis. *Pediatric dentistry*. 2017;39(1):16-123.
6. Dhar V, Marghalani AA, Crystal YO, Kumar A, Ritwik P, Tulunoglu O, et al. Use of Vital Pulp Therapies in Primary Teeth with Deep Caries Lesions. *Pediatric dentistry*. 2017;39(5):146-59.
7. Nematollahi H, Noorollahian H, Bagherian A, Yarbakht M, Nematollahi S. Mineral Trioxide Aggregate Partial Pulpotomy Versus Formocresol Pulpotomy: A Randomized, Split-Mouth, Controlled Clinical Trial with 24 Months Follow-Up. *Pediatric dentistry*. 2018;40(3):184-9.
8. Junqueira MA, Cunha NNO, Caixeta FF, Marques NCT, Oliveira TM, Moretti A, et al. Clinical, Radiographic and Histological Evaluation of Primary Teeth Pulpotomy Using MTA And Ferric Sulfate. *Braz Dent J*. 2018;29(2):159-65.
9. Araujo LB, Cosme-Silva L, Fernandes AP, Oliveira TM, Cavalcanti BDN, Gomes Filho JE, et al. Effects of mineral trioxide aggregate, Biodentine™ and calcium hydroxide on viability, proliferation, migration and differentiation of stem cells from human exfoliated deciduous teeth. *J Appl Oral Sci*. 2018;26:e20160629.
10. Rajasekharan S, Martens LC, Vandembulcke J, Jacquet W, Bottenberg P, Cauwels RG. Efficacy of three different pulpotomy agents in primary molars: a randomized control trial. *Int Endod J*. 2017;50(3):215-28.
11. Parisay I, Ghoddusi J, Forghani M. A review on vital pulp therapy in primary teeth. *Iranian endodontic journal*. 2015;10(1):6-15.
12. Hirschman WR, Wheeler MA, Bringas JS, Hoen MM. Cytotoxicity comparison of three current direct pulp-capping agents with a new bioceramic root repair putty. *J Endod*. 2012;38(3):385-8.
13. Quality guidelines for endodontic treatment: consensus report of the European Society of Endodontology. *Int Endod J*. 2006;39(12):921-30.
14. Hasselgren G, Reit C. Emergency pulpotomy: pain relieving effect with and without the use of sedative dressings. *J Endod*. 1989;15(6):254-6.
15. Fuks AB. Current concepts in vital primary pulp therapy. *European journal of paediatric dentistry*. 2002;3(3):115-20.
16. Lin PY, Chen HS, Wang YH, Tu YK. Primary molar pulpotomy: a systematic review and network meta-analysis. *Journal of dentistry*. 2014;42(9):1060-77.
17. Cvek M, Cleaton-Jones PE, Austin JC, Andreasen JO. Pulp reactions to exposure after experimental crown fractures or grinding in adult monkeys. *Journal of endodontics*. 1982;8(9):391-7.
18. American Academy of Pediatric Dentistry., Best practice on recommendations for pulp therapy for primary and immature permanent teeth. *Pediatr Dent*. 2017;39(6):325-33.
19. Schröder U, Szpringer-Nodzak M, Janicha J, Wacińska M, Budny J, Mlosek K. A one-year follow-up of partial pulpotomy and calcium hydroxide capping in primary molars. *Endodontics & dental traumatology*. 1987;3(6):304-6.
20. Trairatvorakul C, Koothiratrakarn A. Calcium hydroxide partial pulpotomy is an alternative to formocresol pulpotomy based on a 3-year randomized trial. *International journal of paediatric dentistry*. 2012;22(5):382-9.
21. Parirokh M, Torabinejad M, Dummer PMH. Mineral trioxide aggregate and other bioactive endodontic cements: an updated overview - part I: vital pulp therapy. *International endodontic journal*. 2018;51(2):177-205.

22. Peng L, Ye L, Tan H, Zhou X. Evaluation of the formocresol versus mineral trioxide aggregate primary molar pulpotomy: a meta-analysis. *Oral surgery, oral medicine, oral pathology, oral radiology, and endodontics*. 2006;102(6):e40-4.
23. Sushynski JM, Zealand CM, Botero TM, Boynton JR, Majewski RF, Shelburne CE, et al. Comparison of gray mineral trioxide aggregate and diluted formocresol in pulpotomized primary molars: a 6- to 24-month observation. *Pediatric dentistry*. 2012;34(5):120-8.
24. Schulz KF, Altman DG, Moher D. CONSORT 2010 statement: updated guidelines for reporting parallel group randomized trials. *Annals of internal medicine*. 2010;152(11):726-32.
25. Kurji ZA, Sigal MJ, Andrews P, Titley K. A retrospective study of a modified 1-minute formocresol pulpotomy technique part 1: clinical and radiographic findings. *Pediatric dentistry*. 2011;33(2):131-8.
26. Casas MJ, Kenny DJ, Judd PL, Johnston DH. Do we still need formocresol in pediatric dentistry? *Journal (Canadian Dental Association)*. 2005;71(10):749-51.
27. Fernandes AP, Lourenço Neto N, Teixeira Marques NC, Silveira Moretti AB, Sakai VT, Cruvinel Silva T, et al. Clinical and radiographic outcomes of the use of Low-Level Laser Therapy in vital pulp of primary teeth. *International journal of paediatric dentistry*. 2015;25(2):144-50.
28. Stringhini Junior E, Vitcel ME, Oliveira LB. Evidence of pulpotomy in primary teeth comparing MTA, calcium hydroxide, ferric sulphate, and electrosurgery with formocresol. *European archives of paediatric dentistry : official journal of the European Academy of Paediatric Dentistry*. 2015;16(4):303-12.
29. Bogen G, Kim JS, Bakland LK. Direct pulp capping with mineral trioxide aggregate: an observational study. *Journal of the American Dental Association (1939)*. 2008;139(3):305-15; quiz -15.
30. Farsi N, Alamoudi N, Balto K, Mushayt A. Success of mineral trioxide aggregate in pulpotomized primary molars. *The Journal of clinical pediatric dentistry*. 2005;29(4):307-11.
31. Subramaniam P, Konde S, Mathew S, Sugnani S. Mineral trioxide aggregate as pulp capping agent for primary teeth pulpotomy: 2 year follow up study. *The Journal of clinical pediatric dentistry*. 2009;33(4):311-4.
32. Noorollahian H. Comparison of mineral trioxide aggregate and formocresol as pulp medicaments for pulpotomies in primary molars. *British dental journal*. 2008;204(11):E20.
33. Fernández CC, Martínez SS, Jimeno FG, Lorente Rodríguez AI, Mercadé M. Clinical and radiographic outcomes of the use of four dressing materials in pulpotomized primary molars: a randomized clinical trial with 2-year follow-up. *International journal of paediatric dentistry*. 2013;23(6):400-7.
34. Petrolo F, Comba A, Scansetti M, Alovise M, Pasqualini D, Berutti E, et al. Effects of light-cured MTA like material on direct pulp capping. *Dental Materials*. 2014(30):e151.
35. Erfanparast L, Iranparvar P, Vafaei A. Direct pulp capping in primary molars using a resin-modified Portland cement-based material (TheraCal) compared to MTA with 12-month follow-up: a randomised clinical trial. *European archives of paediatric dentistry : official journal of the European Academy of Paediatric Dentistry*. 2018;19(3):197-203.
36. Sahar M, Salwa A, Elagamy R. Clinical and Periapical Radiographic Evaluation of TheraCal and Calcium Sulphate Versus Formocresol as Pulpotomy Agents in Primary Molars. *Mansoura Journal of Dentistry*. 2019;6(2):80-3.
37. Abdullah H, Wassel M, Abd-Elaziz A, M F. Evaluation of A Light-Cured Calcium Silicate (Theracal Lc) in Primary Molars Pulpotomy after 12 Months; A Randomized Controlled Trial. *International Journal of clinical studies & medical case reports*. 2020;8(1):001.
38. Lee H, Shin Y, Kim SO, Lee HS, Choi HJ, Song JS. Comparative Study of Pulpal Responses to Pulpotomy with ProRoot MTA, RetroMTA, and TheraCal in Dogs' Teeth. *Journal of endodontics*. 2015;41(8):1317-24.
39. Ozdemir Y, Kutukculer N, Topaloglu-Ak A, Kose T, Eronat C. Comparative evaluation of pro-inflammatory cytokine levels in pulpotomized primary molars. *Journal of oral science*. 2015;57(2):145-50.
40. Anwari BM, Rasheed M, Naz S, Yousaf RI, Bashir A. Histological Comparison of Honey with Formocresol in Partial Pulpotomy of Deciduous Molars. *National Editorial Advisory Board*. 2020;31(12):72.

<i>Image</i> <i>Author -1</i>	<i>Ahmed Said Abdelhafez</i> <i>Mansoura University</i> <i>Mnasoura /Mansoura</i>
<i>Image</i> <i>Author -2</i>	<i>Abeer Mostafa Abdellatif</i> <i>Mansoura University</i> <i>Mansoura/Mansoura</i>
<i>Image</i> <i>Author -3</i>	<i>Salwa Mohamed Awad</i> <i>Mansoura University</i> <i>Mansoura/Mansoura</i>
<i>Image</i> <i>Author -4</i>	<i>Hossam Elsherbiny Hamoda</i> <i>Mansoura University</i> <i>Mansoura/Mansoura</i>

