


Human Journals

Review Article

October 2021 Vol.:19, Issue:4

© All rights are reserved by Neelam Das

Peri-Implant Diseases: Basics and Beyond



IJSRM
INTERNATIONAL JOURNAL OF SCIENCE AND RESEARCH METHODOLOGY
An Official Publication of Human Journals



Neelam Das

*Department of Periodontology
Rama Dental College, Hospital & Research Centre,
Kanpur (UP)- 208024 India*

Submitted: 24 September 2021
Accepted: 30 September 2021
Published: 30 October 2021



www.ijsrm.humanjournals.com

Keywords: Biological complications, Dental implants, Osseointegration, Peri-implantitis.

ABSTRACT

Contemporarily, the dental implant is considered as the gold standard for managing complete or partially edentulous patients. Even though with meager rates of failure, peri-implantitis is one complication that is worth deciphering. The prevalence of peri-implantitis is reportedly increasing with time so correct diagnosis is the most important factor for proper management of the peri-implant disease. Regular evaluation and elimination of risk factors are effective precautions against peri-implantitis. The management of peri-implant mucositis is also considered as an important preventive measure for the onset of peri-implantitis. In addition to aspects of osseointegration, type and structure of the implant surface are of importance. For the treatment of peri-implant disease multiple conservative and surgical methods are available. This constitutes a concern for clinicians and patients given the negative impact on the quality of life and the sequelae originated by peri-implantitis lesions. To minimize its detrimental effects, it is important to take a holistic view of the condition. The purpose of this narrative review is to report on the prevalence of peri-implant disease and to overview the indications, contraindications, complexity, predictability and effectiveness of the different surgical therapeutic modalities to manage this disorder.

INTRODUCTION

Current Scenario of Peri-Implant Mucositis and Peri Implantitis

Biological issues affecting osseointegrated implants are a subject matter of foremost pastime in current dentistry. Such problems in the main refer to inflammatory stipulations related to a bacterial challenge. Two scientific types can also be distinguished: Peri-Implant Mucositis and Peri-Implantitis.

At the 2017 World Workshop on the Classification of Periodontal and Peri-implant Diseases and Conditions, new disorders and case definitions had been introduced for peri-implant health, peri-implant mucositis and peri-implantitis.¹ Epidemiologic review on peri-implant ailments throughout the globe established a huge vary in accordance to the populace screened and the case definition adopted. Originally, up to 0.2 mm of bone loss around implants in the first year, then 0.1 mm per year subsequently, used to be deemed inside ideal limits.² However, as methods improve, much less bone loss is expected. A bone loss exceeding perfect limits threatens implant success and consequently requires intervention.

Current Definition

In the context of **the Seventh European Workshop on Periodontology in 2011**³ used to be mounted to the definition of **Peri-implant Mucositis** describes a bacteria-induced, reversible inflammatory system of the peri-implant gentle tissue with reddening, swelling, and bleeding on periodontal probing. These are common signs, however, they are now and then no longer virtually visible.⁴

Peri-implantitis is a pathological situation happening in tissues round dental implants, characterized by using infection in the peri-implant mucosa and revolutionary loss of helping bone. In the scientific setting, gentle tissue infection is detected through probing (bleeding on probing, BOP), whilst revolutionary bone loss is recognized on radiographs.⁴

Classification of Peri-Implant Mucositis and Peri-Implantitis

A classification for peri-implant mucositis and peri-implantitis based on the severity of the disease, using a combination of peri-implant clinical and radiological parameters to classify severity into several stages.⁵

Table 1. Proposed classification of peri-implant mucositis.

STAGING	DEFINITION
Stage 0A	PPD ≤ 4 mm and BOP and/or SUP, with no signs of loss of supporting bone following initial bone remodeling during healing
Stage 0B	PPD > 4 mm and BOP and/or SUP, with no signs of loss of supporting bone following initial bone remodeling during healing.

PPD = probing pocket depth; BOP = bleeding on probing; SUP = suppuration

Table 2. Proposed classification of peri-implantitis.

STAGING	DEFINITION
Stage I	BOP and/or SUP and bone loss ≤ 3 mm beyond biological bone remodeling.
Stage II	BOP and/or SUP and bone loss > 3 mm and < 5 mm beyond biological bone remodeling.
Stage III	BOP and/or SUP and bone loss ≥ 5 mm beyond biological bone remodeling.
Stage IV	BOP and/or SUP and bone loss ≥ 50% of the implant length* beyond biological bone remodeling.

BOP = bleeding on probing; SUP = suppuration

* Depending on **implant length**, if Peri-implantitis can be classified as simultaneously corresponding to more than one stage, the most advanced stage should be chosen.⁵

Prevalence Rate

Prevalence of peri-implantitis was once evaluated and published that 10% of all inserted implants and 20% of all implanted patients showed peri-implantitis. Peri-implantitis results from an imbalance between the host response and oral biofilm at the implant surfaces.⁶

Characteristics of Peri-Implant Tissue

On a microscopic and molecular level, striking differences between peri-implant tissue and intact periodontium can be determined (Table 3). Due to the reduced vascularization and parallel orientation of the collagen fibers, peri-implant tissues are more susceptible for inflammatory disease than periodontal tissues.⁷

Table 3. Comparison of peri-implant mucosa with physiological periodontium.⁸

PERI-IMPLANT MUCOSA	PHYSIOLOGICAL PERIODONTIUM
Desmosomes and hemidesmosomes of epithelium and junctional epithelium (biological width) are linked with the contact surface	
Direct bone-to-implant contact	The anchoring system of root cementum, alveolar bone and desmodromic fibers
Subepithelial more collagen fibers and less fibroblasts/vessels	Subepithelial more fibroblasts and vessels
Parallel collagen fibers in relation to implant surface	Dentogingival, dentoperiostal, circular and transseptal fiber orientation

This phenomenon can be verified immuno-histochemically through increased formation of inflammatory infiltrate, nitric oxide 1/3, VEGF, lymphocytes, leukocytes and Ki-67. Besides, in analogy to periodontitis the level of matrix metalloproteinases (MMP), such as MMP-8, is increased up to 97% in peri-implant lesions.⁹ The latter can be used for diagnostic purposes. A differentiation of peri-implantitis to other inflammatory periodontal processes cannot be made based on salivary biomarkers such as osteocalcin, tartrate-resistant acid phosphatase (TRAP), dickkopf-related protein-1 (DKK-1), osteoprotegerin (OPG) and cathepsin K (CatK).¹⁰

Onset and Pattern of Disease Progression

There are broadly three theories currently proposed to explain the aetiopathogenesis of peri-implantitis:

[1] A pathogenic microbial plaque is necessary, albeit insufficient.

[2] The disease is the result of micro-movement of the implant.

[3] A compromise in the host healing and adaptation predisposes to peri-implantitis.

The microbial biofilm associated with the peri-implant disease is mixed and variable, although generally dominated by Gram-negative anaerobic bacteria. Research indicated that peri-implantitis may be associated with an increased proportion of **Porphyromonas. gingivalis, Treponema denticola, Fusobacterium.nucleatum, and Aggregatibacter. actinomycetemcomitans.**¹¹ In addition to the microbiological theory for implant bone loss, there is also experimental evidence that excessive or adverse loading may cause advancing bone resorption. A further postulated theory is that of ‘**The Compromised Healing/ Adaptation Theory**’. In this theory, implant anchorage is disturbed by way of bad surgical technique, killing cells wanted for repair.¹¹

Establishing A Diagnosis

Clinical parameters used in the diagnosis of periodontal affectation are used to establish the diagnosis of peri-implant damage (Figure.1).

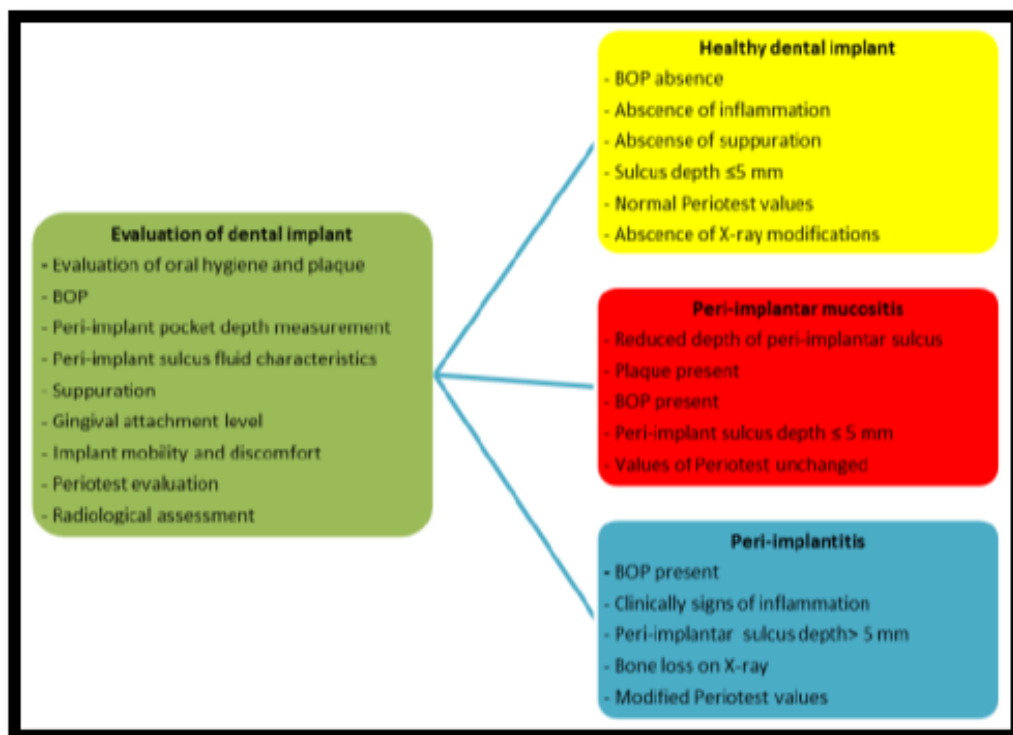


Figure No. 1: Diagnosis and evolution of peri-implant affectation

Risk Indicators

Correct diagnosis is the most important factor for proper management of the peri-implant disease. The risk indicators which result in peri-implant mucositis and peri-implantitis are as follows¹²:-

- [1] Smoking with extra drastically greater hazard of issues in the presence of a tremendous mixed IL-1 genotype polymorphism.
- [2] History of periodontitis.
- [3] Lack of compliance and constrained oral hygiene (including lacking checkups).
- [4] Systemic illnesses (e.g. maladjusted diabetes mellitus, cardiovascular disease, immunosuppression).
- [5] Iatrogenic motives (e.g. “cementitis”).

[6] Soft tissue defects or poor-quality tender tissue at the vicinity of implantation (e.g. lack of keratinized gingiva).

[7] History of one or more failures of implants.

Peri-implant probing is endorsed to be carried out cautiously with a minimal probing force. However, the so-called “**Platform Switch**” (abutment is positioned horizontally between implant and crown) can complicate probing and, thus, conceal the real extension of peri-implantitis. Nevertheless, research has indicated that **Platform Switch** may be a necessary shielding thing against peri-implant disease.¹³

Implant loss can be differentiated on the basis of the following additional factors¹⁴:-

[1] Overloading of the implant.

[2] Faults in material and techniques.

[3] Poor bone quality at the implant area.

[4] Systemic diseases and drug therapies, which inhibit bone modulations in accordance to “**Wolff’s law**” (bone density and strength increase with stress - and vice versa).

Prevention

Pre-Installation- All risk factors for periodontal ailments ought to be assessed and managed as long way as is possible. Periodontal cure needs to be performed and there ought to have been an adequate length of supportive remedy to expect stability.

Post Implant Placement-A follow-up program for early detection of peri-implant ailments ought to include:

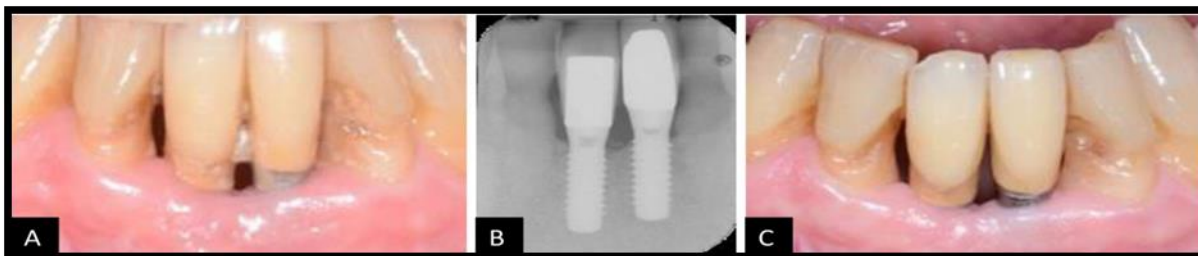
[1] Periodontal status, which includes Oral Hygiene and BOP and risk factors.

[2] Peri-implant pocket depths (using stainless metal or plastic periodontal probes).

[3] Radiographic findings (first at the year overview appointment and thereafter, if there is a clinical indication).

Clinical Implications

Case Presentation 1- Non-Surgical treatment of peri-implantitis.

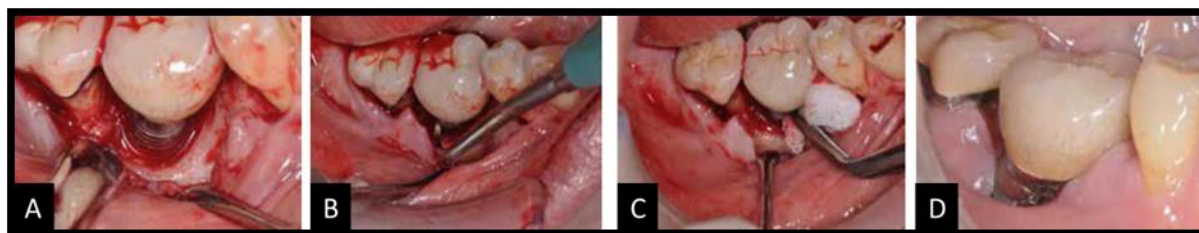


Case 1A: Peri-implant mucositis at implants 41 and 31. The presence of bacterial biofilms can be observed on the implant surfaces as well as on the roots of the adjacent teeth.

Case 1B: Periapical radiograph of tissue level implants 41 and 31 illustrating lack of supporting bone.

Case 1C: Buccal view of implants 41 and 31 six months following mechanical debridement and oral hygiene instruction. The implants are surrounded by healthy mucosa and absence of bacterial biofilms can be observed.

Case Presentation 2 - Surgical treatment of peri-implantitis.



Case 2A: Soft tissue flap reflected to expose the remaining peri-implant bone.

Case 2B: Debridement of the implant surface with titanium scaler.

Case 2C: Disinfection of implant surface with 2% chlorhexidine soaked gauze.

Case 2D: Soft tissue closure and recession resulting in stable peri-implant soft tissue with probing pocket depth less than 4 mm in all sites.

Treatment Protocol

The main step in any treatment that addresses peri-implant tissues is the debridement of affected areas and implant surface decontamination. Thus, the treatment can be divided into two categories: treatment of peri-implantar mucositis and treatment of peri-implantitis.

While mucositis treatment is a non-surgical treatment, peri-implantitis management may include surgical procedure, correlated with related factors of severity of the damage, aesthetic requirements, presence or absence of the neighboring teeth (Table 4).

Table 4. Treatment protocols suggested for the treatment of peri-implantar affectation

CLINICAL PARAMETERS	CLINICAL DIAGNOSIS	TREATMENT PROTOCOL
Reduced depth of periimplantar sulcus ✓ Absence of plaque ✓ Absence BOP	Healthy Peri-Implantar Tissue	No treatment is needed; regular checks-ups and proper oral hygiene maintenance.
Reduced peri-implantar sulcus depth ✓ Plaque present ✓ BOP	Peri-Implantar Mucositis	A. Mechanical debridement and polishing surfaces with rubber cups and nonabrasive paste. Regular check-ups and monitoring of oral hygiene.
Peri-implantar sulcus depth \leq 5 mm	Peri-Implantar Mucositis	B. Treatment includes A and surfaces cleaning using an antiseptic.
Peri-implantar sulcus depth $>$ 5 mm associated with a loss of bone up to 2 mm	Peri-Implantitis	C. Treatment includes B and the use of local and systemic antibiotics.
Peri-implantar sulcus depth $>$ 5 mm associated with bone loss $>$ 2 mm	Severe Peri-Implantitis	D. Treatment includes C combined with regenerative surgical procedure (flap technique or GBR).

Treatment of Peri-Implant Diseases

It is universally time-honored that the microbial biofilm performs a central function in the disease and its disruption is required for profitable treatment. Before moving forward treatment, iatrogenic elements that may also promote peri-implantitis or mucositis must be recognized and, if possible, addressed eg: excess cement, over-contoured restorations or poorly positioned implants.¹⁵

Therapy of Peri-Implant Mucositis¹⁶

[1] **Professionally administered mechanical debridement-** To remove supra- and sub-mucosal calculus and biofilm deposits, hand instruments including titanium or carbon-fiber curescopes and/or ultrasonic devices with various tips may be used.

[2] **Air-polishing biofilm removal-** Air-polishing devices represent a choice to hand-driven gadgets for the supra- and submucosal elimination of biofilm deposits. The most usually used powders are glycine, sodium bicarbonate and erythritol and are high quality in putting off biofilms from machined and modified titanium and zirconia implants besides inflicting important floor alterations.

[3] **Adjunctive measures-** Adjunctive measures to mechanical debridement including local antimicrobials, air-polishing, diode laser irradiation, photodynamic therapy and probiotics may be used.

[4] **Adjunctive local antiseptics-** Following mechanical debridement with plastic curescopes in patients diagnosed with peri-implant mucositis, a 0.12% chlorhexidine digluconate solution was delivered into peri-implant pockets.

[5] **Adjunctive systemic antimicrobials-** The outcomes of adjunctive systemic antimicrobials (i.e. Azithromycin) have been investigated for the administration of peri-implant mucositis.

[6] **Adjunctive probiotics-** It has been postulated that everyday oral delivery of probiotic microorganisms might also assist the formation of bacterial biofilms well suited with peri-implant fitness and thereby enhance clinical, microbiological and host-derived parameters when

administered as adjuncts to non-surgical mechanical debridement of peri-implant mucositis eg: daily oral delivery of probiotics containing **Lactobacillus Reuteri** for 30 days.

[7] **Adjunctive laser irradiation**-The adjunctive consequences of diode laser irradiation with a wavelength of 980 nm are used in patients diagnosed with peri-implant mucositis.

[8] **Adjunctive antimicrobial photodynamic therapy (aPDT)**- Peri-implant mucositis indicated that antimicrobial photodynamic therapy as an adjunct to mechanical therapy resulted in an additional significant reduction of PPD compared with mechanical debridement therapy.

Therapy of Peri-Implantitis¹⁷

I) Non-Surgical Management of Peri-Implantitis

[1] **Non-surgical debridement**-Supra- and submucosal debridement at implants identified with peri-implantitis may additionally be carried out the use of hand- and/or power-driven instruments, laser irradiation or air-polishing.

[2] **Adjunctive local antiseptics and antimicrobials**-Mechanical implant surface debridement in conjunction with the placement of non-resorbable tetracycline-impregnated fibers yielded statistically significant clinical improvements with respect to reduction in mean PPD and BOP scores eg: locally delivered minocycline microspheres.

[3] **Adjunctive systemic antimicrobials**-The clinical advantages of adjunctive systemic antimicrobials in the non-surgical treatment of advanced peri-implantitis.

[4] **Laser irradiation**-The Er: YAG (erbium-doped: yttrium, aluminum and garnet) laser is the most in many instances investigated laser for remedy of peri-implantitis. Its emission wavelength of 2940 nm is fairly absorbed in water imparting excessive functionality of casting off non-mineralized and mineralized biofilms from implants besides unfavorable their surfaces or inflicting thermal harm to the adjoining tissues.

[5] **Air-polishing**-The use of air-polishing devices with glycine powder yielded greater reductions in BOP-positive sites compared with either mechanical debridement with/without adjunctive local antiseptics or with Er: YAG laser monotherapy.

[6] **Adjunctive antimicrobial photodynamic therapy (aPDT)**-Application of aPDT has been used as an additional approach for decontamination of implants affected using peri-implantitis.

II) Surgical Management of Peri-Implantitis¹⁸

[1] **Open flap surgical procedure**-The important goal of the surgical cure is the introduction of a direct get entry to the contaminated site, facilitating cleanup and elimination of granulation tissue. Also, surgical protocol determination is made based totally on the degree of morphology peri-implantar bone defect achieved.

[2] **Surgical resection with or except amendment of implant floor (Implantoplasty)**-Surgical resection is used in the remedy of peri-implantitis to right smooth and hard. The goal of the remedy is to cast off periodontal pockets the use of gingival flaps or to minimize apical crevicular sulcus to make it a greater low cost for prophylactic procedures. Surgical resection may also additionally contain bone elimination or reshaping of a portion. Another alternative is implantoplasty.

[3] **Guided bone regeneration treatment**-The regenerative healing procedures are open filed interventions, with mechanical debridement and grafting additions collectively or mixed with membranes. Membranes guard the graft fabric and grant house for tissue formation. When used besides tissue membrane, the grafting technique is referred to as guided bone regeneration (GBR).

[4] **Other reasons of peri-implantar crestal bone loss**-The peri-implantitis is no longer the solely thing that motives bone resorption. Around osseointegrated implants, in the first 12 months after useful loading, there is a about 1 mm. Supra-loading of implants is now not a direct thing for the improvement of peri-implantitis, however, set off a bone injury leads to accelerated resorption.

CONCLUSION

Peri-implantitis is an extreme complication that consequences in the failure of dental implants. Therefore, prevention is the most necessary instrument primarily based on suitable remedy planning, an a stressful strategy for implant insertion and non-stop check-up intervals with expert

enamel and implant cleaning. Above all, interest ought to be paid to hazard elements such as smoking and energetic or preceding periodontitis. A non-surgical therapy, extra cure picks and surgical remedy are recommendable.

A graded systematic remedy planning in accordance to the Cumulative Interceptive Supportive Therapy protocol can be recommended. The “ideal peri-implantitis therapy” is a sum of methods main to an person remedy regime regarding multifactorial etiology, cure options.¹⁹

Author Contributions: The author was contributed to update all relevant information to formulate the design, drafted the manuscript review. The authors gave final approval and agree to be accountable for all aspects of the work.

Financial support and sponsorship: Nil.

Conflicts of interest: There are no conflicts of interest.

Competing interests: The author declares that she has no competing interests with regards to authorship or publication of this paper.

REFERENCES

- 1) Berglundh T, Armitage G, Araujo MG, Gustavo AO, Juan B, Paulo MC *et al.* Peri-implant diseases and conditions: Consensus report of workgroup 4 of the 2017 World Workshop on the Classification of Periodontal and Peri-Implant Diseases and Conditions. *J. Periodontol* 2018; 8(9): 313–18.
- 2) Albrektsson T, Zarb G, Worthington P, Eriksson AR. The longterm efficacy of currently used dental implants: a review and proposed criteria of success. *Int J Oral Maxillofac Implants* 1986; 1: 11-25.
- 3) Lang NP, Berglundh T. Working Group 4 of Seventh European Workshop on Periodontology. Periimplant diseases: where are we now? Consensus of the Seventh European Workshop on Periodontology. *J Clin Periodontol* 2011; 38: 178-81.
- 4) Lindhe J, Meyle. Peri-implant mucositis and peri-implantitis: a current understanding of their diagnoses and clinical implications. *J Periodontol* 2013; 84: 436-43.
- 5) Ata-Ali J, Candel-Marti ME, Flichy-Fernandez AJ, Balaguer-Martinez JF, Diago PM. Peri-implantitis: associated microbiota and treatment. *Med Oral Patol Oral Cir Bucal* 2011; 16: 937-43.
- 6) Aguirre LA, Estefania R, Telletxea O. Prevalence of peri-implant inflammatory disease in patients with a history of periodontal disease who receive supportive periodontal therapy. *Clin Oral Implant Res* 2015; 26: 1338–44.
- 7) Khammissa RAG, Feller L, Meyerov R, Lemmer J. Peri-implant mucositis and peri-implantitis: clinical and histopathological characteristics and treatment. *SADJ* 2012, 67(122): 124–26.
- 8) Wilson V: An insight into peri-implantitis: a systematic literature review. *Prim Dent J* 2013, 2: 69–73.
- 9) Degidi M, Artese L, Piattelli A, Scarano A, Shibli JA, Piccirilli M *et al.* Histological and immunohistochemical evaluation of the periimplant soft tissues around machined and acid-etched titanium healing abutments: a prospective randomised study. *Clin Oral Investig* 2012; 16: 857–66.

- 10) Xu L, Yu Z. Characteristics of collagenase-2 from gingival crevicular fluid and peri-implant sulcular fluid in periodontitis and peri-implantitis patients: pilot study. *Acta OdontolScand* 2008; 66: 219–24.
- 11) Berglundh T, Zitzmann NU, Donati M. Are peri-implantitis lesions different from periodontitis lesions? *J Clin Periodontol* 2011; 38: 188–202.
- 12) Heitz-Mayfield LJ. Peri-implant diseases: diagnosis and risk indicators. *J Clin Periodontol* 2019; 35:292–304.
- 13) Al Nsour MM, Chan HL, Wang HL. Effect of the platform-switching technique on preservation of peri-implant marginal bone: a systematic review. *Int J Oral Maxillofac Implants* 2012; 27:138–45.
- 14) Flanagan D, Ilies H, Lasko B, Stack J. Force and movement of Non-osseointegrated implants: an in vitro study. *J Oral Implantol* 2019; 35: 270–76.
- 15) Mattheos N, Collier S, Walmsley AD. Specialists' management decisions and attitudes towards mucositis and peri-implantitis. *Br Dent J* 2012; 212(1): E1–E.
- 16) Menezes KM, Fernandes-Costa AN. Efficacy of 0.12% Chlorhexidine Gluconate for Non-Surgical Treatment of Peri-Implant Mucositis. *J Periodontol* 2017; 87(11): 1305–13.
- 17) Roos-Jansaker AM, Jansson H. Treatment of peri-implantitis: clinical outcome of chloramine as an adjunctive to non-surgical therapy, a randomized clinical trial. *Clin Oral Implants Res* 2018; 28(1): 43–8.
- 18) Froum SJ, Froum SH, Rosen PS. Successful management of peri-implantitis with a regenerative approach: a consecutive series of 51 treated implants with 3- to 7.5-year follow-up. *Int J Periodont Rest Dent* 2012; 32(1): 11–20.
- 19) Schwarz F, Derks J, Monje A, Wang HL. Peri-implantitis. *J Clin Periodontol* 2018; 45(20): 246–66.

