



IJSRM

INTERNATIONAL JOURNAL OF SCIENCE AND RESEARCH METHODOLOGY

An Official Publication of Human Journals



Human Journals

Review Article

December 2020 Vol.:17, Issue:2

© All rights are reserved by Sagarla Hema et al.

Craniosynostosis



IJSRM
INTERNATIONAL JOURNAL OF SCIENCE AND RESEARCH METHODOLOGY
An Official Publication of Human Journals



Dunaboina Poojitha Sangavi, Kathi Sandhya, Sagarla Hema*

*4th year Pharm.D, Pulla Reddy Institute of Pharmacy,
India.*

Submitted: 12 November 2020
Revised: 02 December 2020
Accepted: 22 December 2020

Keywords: Birth defect; craniosynostosis; craniofacial.

ABSTRACT

Craniosynostosis is a developmental craniofacial anomaly, resulting in impairment of brain development and an abnormally shaped skull. The main cause of craniosynostosis is the premature closure of one or more cranial sutures. Craniosynostosis is classified according to sutures and frequencies of these different types of craniosynostosis are as follows sagittal (60%), coronal (25%), metopic (15%), and lambdoid (2%). Craniosynostosis is usually clinical and it is commonly diagnosed in the first year of life. The computerized tomography (CT) with three dimensional (3D) reconstruction is considered the most complete and accurate imaging to diagnose craniosynostosis. The main treatment of craniosynostosis is surgery. Surgeons open the fused fibrous seams (sutures) in your child's skull. Surgery helps the skull grow into a more typical shape and prevents a build-up of pressure in the brain.



HUMAN JOURNALS

www.ijsrm.humanjournals.com

DEFINITION:

Craniosynostosis (Kray-nee-o-sin-os-TOE-sis) is a birth defect in which one or more of the fibrous joints between the bones of your baby's skull (cranial sutures) close prematurely (fuse), before your baby's brain is fully formed brain growth continues, giving the head a misshapen appearance. The spaces between a typical baby's skull bones are filled with flexible material and called sutures.

- At least 20% of cases are caused by specific single-gene mutations or chromosome abnormalities.
- Both environmental factors (especially intrauterine fetal head constraint) and genes (single-gene mutations, chromosome abnormalities and polygenic background) predispose to craniosynostosis.
- Genes most commonly mutated in craniosynostosis are FGFR2, FGFR3, TWIST1 and EFNBI.

The growth occurs predominantly at the narrow seams of undifferentiated Mesenchyme, termed cranial sutures, which lies between different bones. The paired frontal and Parietal bones are separated in the midline by the metopic and sagittal sutures respectively; the frontal and parietal bones are separated by coronal sutures, and parietal bones are separated from the single occipital bone by lambdoid sutures. The overall prevalence of craniosynostosis has been estimated at between 1 in 2100 and 1 in 2500 births. Craniosynostosis is important to recognize and treat because it can be associated with many complications affecting sensory, respiratory, and neurological function.

Left untreated, craniosynostosis can result in further cranial deformity and potential an overall restriction in head growth, with secondary increased intracranial pressure. It can also lead to psychological issues as the child interacts with peers during development.

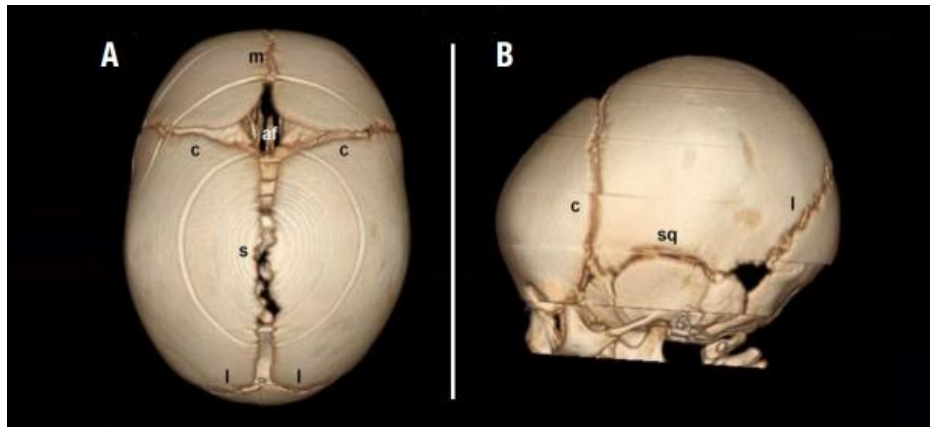
Types:

There are a few different types of craniosynostosis. The types are based on which suture or sutures are affected and the cause of the problem. About 80 to 90% of craniosynostosis cases involve only one suture.

There are two main types of craniosynostosis. Non-syndromic and syndromic, non-syndromic craniosynostosis is the most common type. And it's caused by a combination of genes and environmental factors. Syndromic craniosynostosis is caused by inherited syndromes, such as Apert syndrome, Crouzon syndrome and Pfeiffer syndrome.

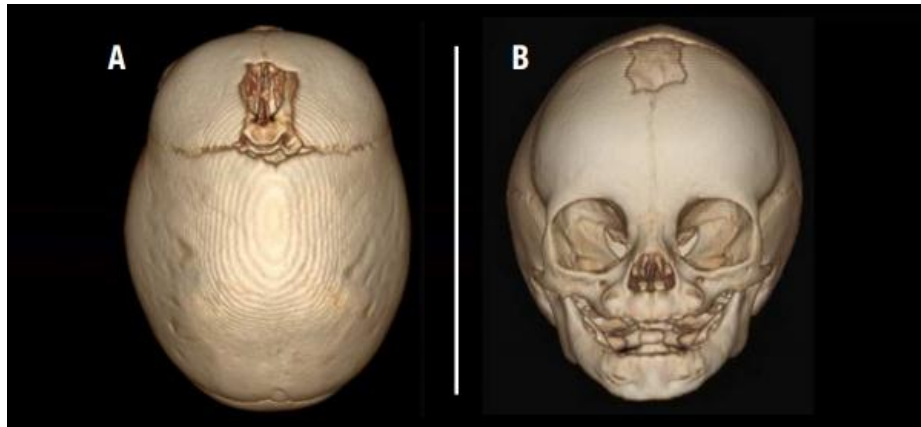
The term given to each type of craniosynostosis depends on what sutures are affected. Types of craniosynostosis include:

- **Normal sutures:** Include the metopic (m), coronal (c), sagittal (s), lambdoid (l), and squamosal (sq). In craniosynostosis, the anterior fontanel (af), or “soft Spot,” may be open or closed.

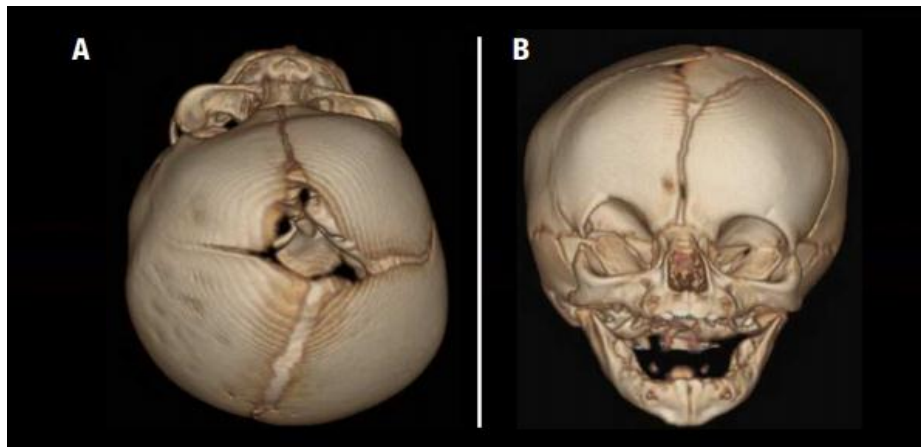


- **Sagittal craniosynostosis:** the most common non-syndromic form that causes premature fusion of the sagittal suture that runs from the front to the back at the top of the skull forces the head to grow long and narrow. Sagittal craniosynostosis results in a head shape called Scaphocephaly and is the most common type of craniosynostosis. There may be prominence, or “bossing,” of the forehead and/or back of the head.

- **Coronal craniosynostosis:**

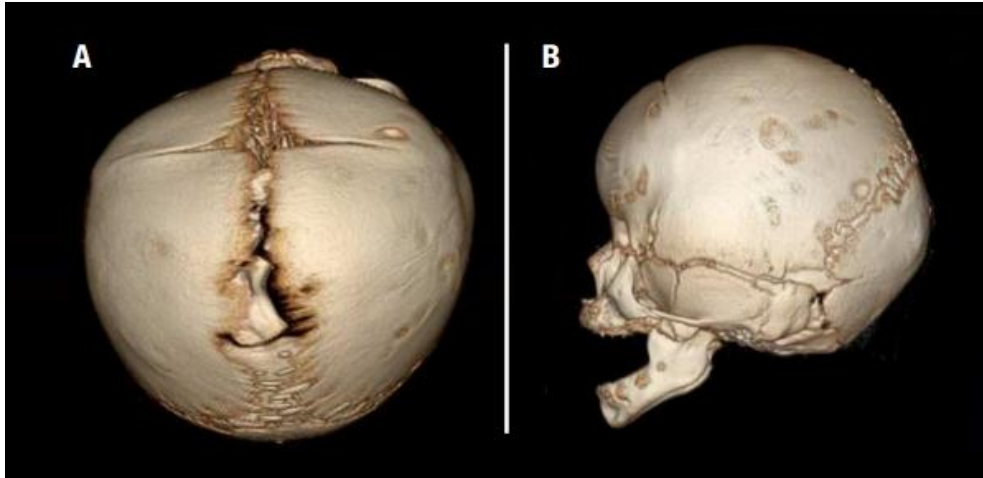


- **Unicoronal:**



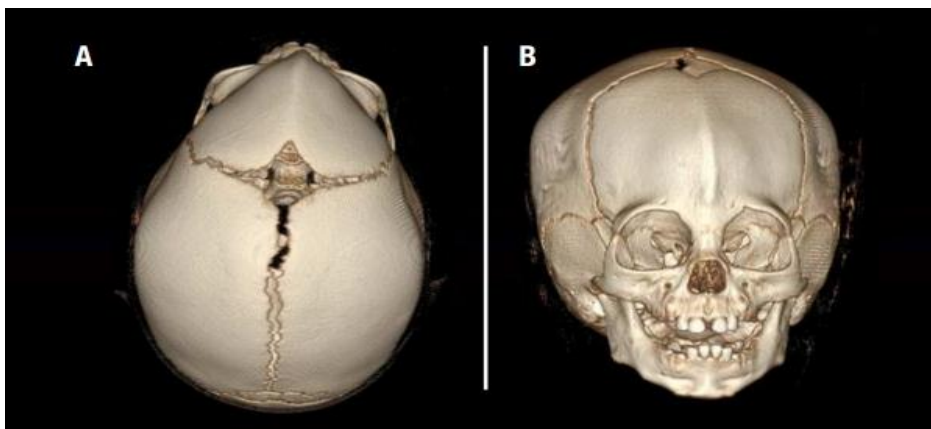
(One side) premature fusion of the coronal sutures that run from each ear to the top of the skull may cause the forehead to flatten on the affected side and bulge on the unaffected side. It also leads to the turning of the nose and a raised eye socket on the affected side. Sometimes the anterior fontanel is somewhat displaced to the opposite side.

Bicoronal:

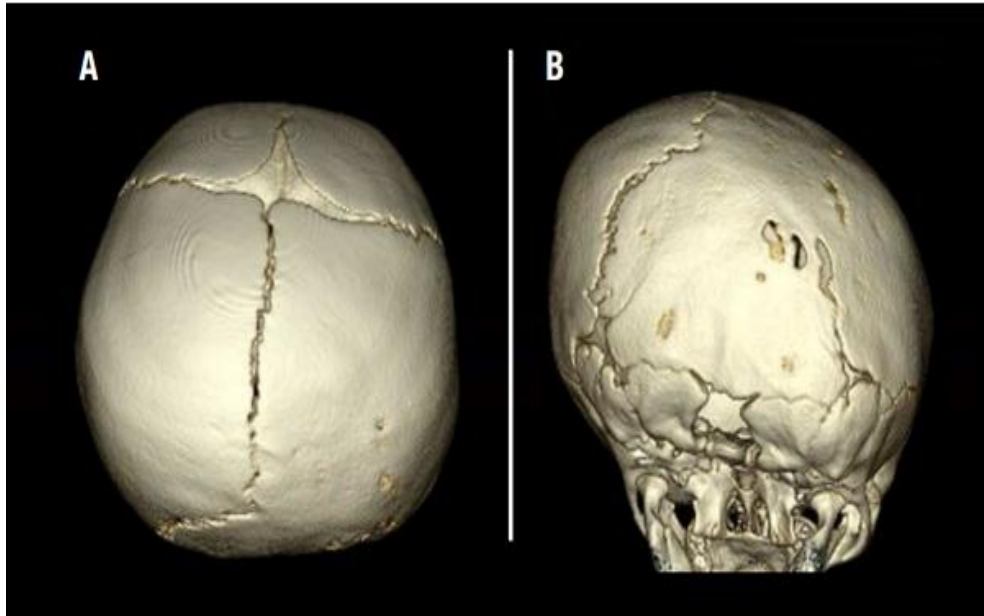


(Both sides) the most common syndromic form, when both coronal sutures fuse prematurely, the head has a short and wide appearance, often with the forehead tilted forward.

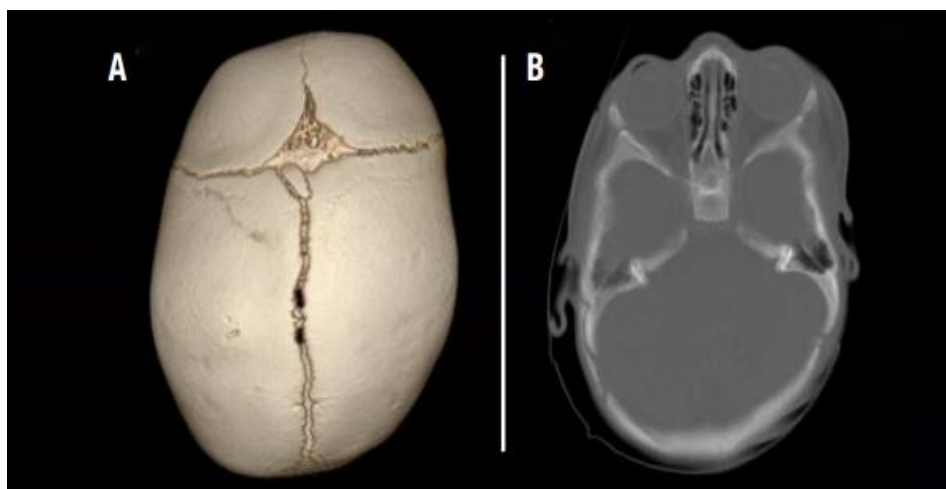
- **Metopic craniosynostosis:** The metopic sutures run from the top of the bridge of the nose up through the midline of the forehead to the anterior fontanel and the sagittal suture. Premature fusion gives the forehead a triangular appearance and widens the back part of the head. This is also called trigonocephaly.



- **Lambdoid craniosynostosis:** lambdoid synostosis is a rare type of craniosynostosis that involves the lambdoid suture, which runs along the back of the head. It may cause one side of your baby's head to appear flat, one ear to be higher than the other ear, and tilting of the top of the head to one side.



- **Positional plagiocephaly** is different than craniosynostosis. In positional plagiocephaly, there is flattening in the back of the head, either the right, the left, or the center. In contrast to lambdoid craniosynostosis, the ear and possibly forehead on the side of the flattening are displaced towards the front, giving the head a parallelogram shape rather than a trapezoid shape.



- **Other multiple suture craniosynostosis** is very rare and can take a number of forms.

Signs and Symptoms of craniosynostosis:

The signs of craniosynostosis are usually noticeable at birth, but they will become more apparent during the first few months of your baby's life. Signs and severity depend on how many sutures are fused and when in brain development the fusion occurs. These can include:

- A misshapen skull, with the shape depending on which of the sutures are affected.
- An abnormal feeling or disappearing fontanel on your baby's skull.
- Development of a raised, hard ridge along affected sutures.
- Slow or no growth of the head as your baby grows.
- The soft spot may be open or closed.

Depending on the types of craniosynostosis your baby has, other symptoms can include:

- Headache
- Nausea
- Vomiting
- Wide or narrow sockets
- Learning disabilities
- Vision loss
- Lethargy
- Difficulty moving eyes up
- Bulging and/or tense soft spot (when the patient is upright and does not have a respiratory infection)
- Seizures
- High-pitched cry
- Developmental delays
- Scalp veins may be very noticeable



ETIOLOGY: often the cause of craniosynostosis is not known, but sometimes it's related to genetic disorders.

- **Non-syndromic craniosynostosis** is the most common type of craniosynostosis, and its cause is unknown, although it's thought to be a combination of genes and environmental factors. Here are some possible explanations:

The fetus assumes a position in the womb that puts pressure on the head and pushes the plates of bones in the skull together.

- **Syndromic craniosynostosis** is caused by certain genetic syndrome's, such as
Apert syndrome
Pfeiffer syndrome
Crouzon syndrome,

This can affect your baby's skull development. These syndromes usually also include other physical features and health problems.

History:

Most of the modern understanding of craniosynostosis is referenced from the 1851 writings of Virchow. His understanding and description of irregular calvarial growth patterns were the basis of the law of Virchow. According to these observations, the abnormal cranial growth observed in persons with craniosynostosis occurs perpendicular to the involved calvarial sutures. Therefore, if a suture line is prematurely ossified, no growth is present in the direction perpendicular to that suture. The law was too simplistic in its explanation of the growth patterns of the skull.

Surgical treatment for craniosynostosis was initially advocated by Lannelongue in 1890. His patients had microcephaly from craniosynostosis and were thought to be imbeciles. These patients accordingly underwent craniectomy to remove the involved suture line and to "release the brain". Soon after, in 1891, linear craniectomy was introduced. As with any new procedure, this one met with much resistance. Several studies indicate that craniosynostectomy was the treatment of choice for the release of fused suture lines in the skull.

Although strip craniectomy was used often, it lost much support with the advent of cranial vault reconstruction in which the calvarial bones were excised, reshaped, and trimmed. Studies showed that over time, cranial suture areas excised during strip craniectomy still became fused and led to an abnormal cranial contour. Strip craniectomy was easier and involved less blood loss

compared with the newer cranial vault reconstruction. Strip craniectomy also did not address the frontal bossing and associated abnormalities in calvarial shape and relied on the rapid growth off the brain to correct it. Strip craniectomy was optimal only in the 1st few months in infancy, while surgeons could use cranial vault reconstruction throughout infancy. Consequently, strip craniectomy lost favor, and Surgical Treatment has been modified to include cranial vault remodeling.

With the advent of endoscopy, Attention has returned to endoscopic strip Craniectomy. The endoscopic technique has only been tried over the last several years, but it offers the advantages of shorter and safer operation, less cost, less in-hospital time, and less blood loss. The operation was shown to be a success in a study of 12 patients, all younger than eight months. Critical to this success and a departure from the standard strip craniectomy was the extensive use of postoperative remodeling helmet. Although first introduced by Persing et al in 1986, Helmet therapy has not been used as extensively as a postoperative therapeutic intervention. Following the endoscopic technique, Helmets were used for several months and showed promising early results.

Rivero-Garvia et al concluded that endoscopy assisted surgery for correction of craniosynostosis in children younger than 4 months represents a valid and safe management option that may help prevent the development of associated ventriculomegaly.

EPIDEMIOLOGY OF CARANIOSYNOSTOSIS: The reported incidence of craniosynostosis varies between 1 in 1600 and 1 in 4000 live births and it seems to be increasing. Syndromic craniosynostosis constitutes between 12% and 31% of all cases. The sagittal suture is the most commonly affected suture, the proportion varying between 41% and 68%. Male and female ratio ranges from 1.8:1 to 4.7:1 and proportional of familial craniosynostosis is reported to be between 5.6% and 14.7%.

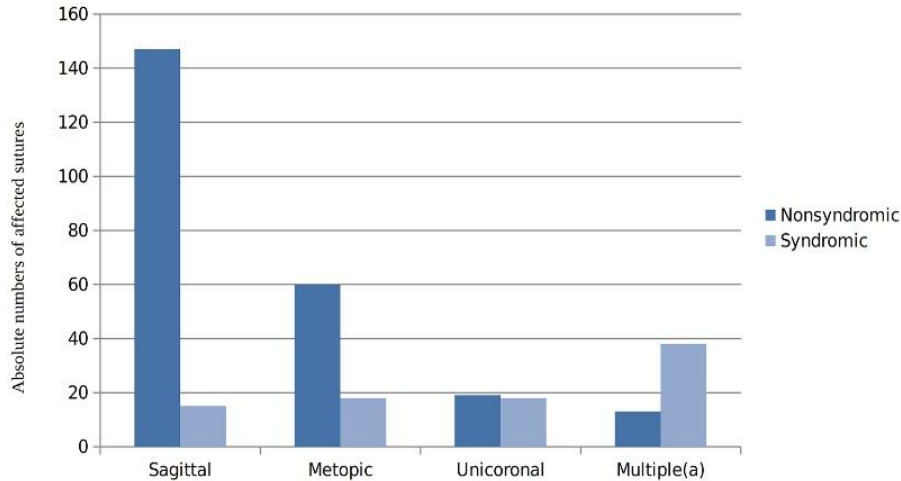


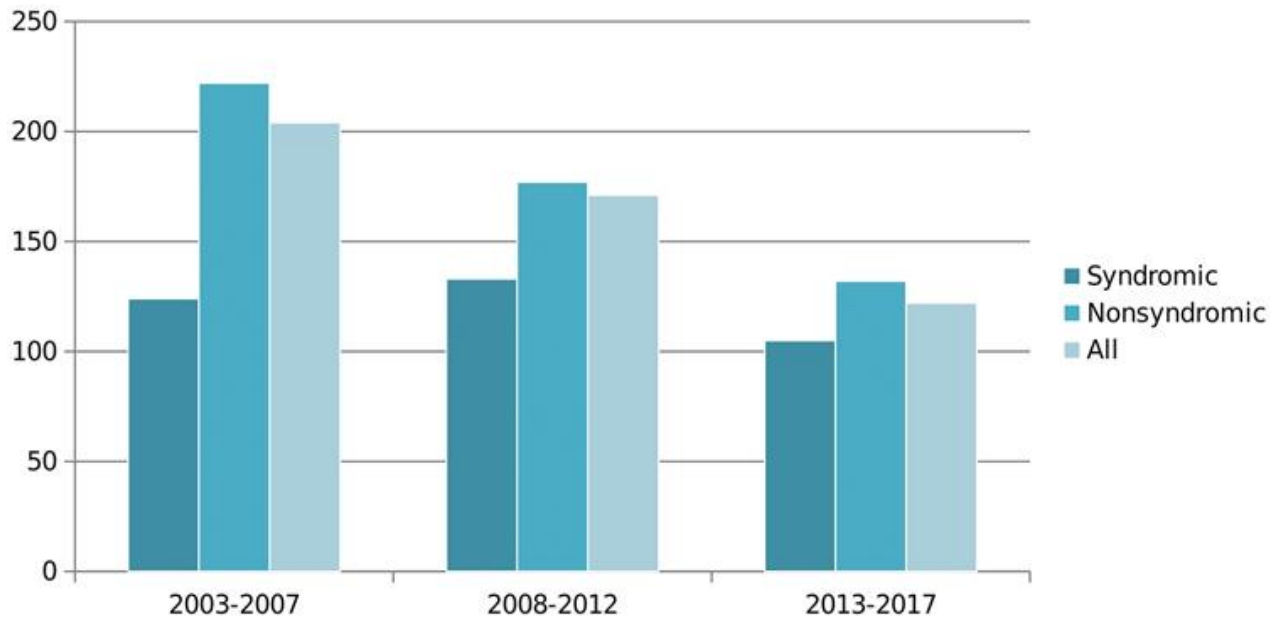
Table No. 1: Affected sutures in non syndromic craniosynostosis and syndromic craniosynostosis presented in absolute numbers and percentages. The incidence increased significantly during study period was 5.5 per 10,000 live births (1/1800) in last 5 year period. The increase was seen almost exclusively in non syndromic group. Syndromic craniosynostosis accounted for 27% of cases and the incidence remained stable throughout the three 5 year periods. Both syndromic and non syndromic craniosynostosis were highly suture specific.

Type of synostosis and Number	Patient age		Increased ICT	Orbital advancement		Operative time (minutes)	Blood loss (%EBV)	Complications		Visible defects
	Age (month)	Number		Done	Aborted			type	number	
Non Syndromic Sagittal N = 12	< 6	2	1			120	49±1.4			
	6-12	5	1			133±11	33.8±4.3	Wound infection	1	
	>12	7	4			142±12	29.4±6.3	Extradural hematoma	1	3
Non Syndromic Metopic N = 6	< 6	1	1		1	150	46	Intraoperative hypovolaemia	1	
	6-12	2	1	2		205±7	52±4.2			
	>12	1				180	36			1
Non Syndromic Bilateral coronal N = 1	6-12	1				240	52	Subgialial CSF leak	1	1
Apert Syndrome N = 2	< 6	2	2	1	1	210±42	40±21.2	Intraoperative hypovolaemia leading to Cardiac arrest	1	
Crouzon Syndrome N = 2	< 6	2	2	1	1	205±15	36±8.5	Intraoperative hypovolaemia	1	

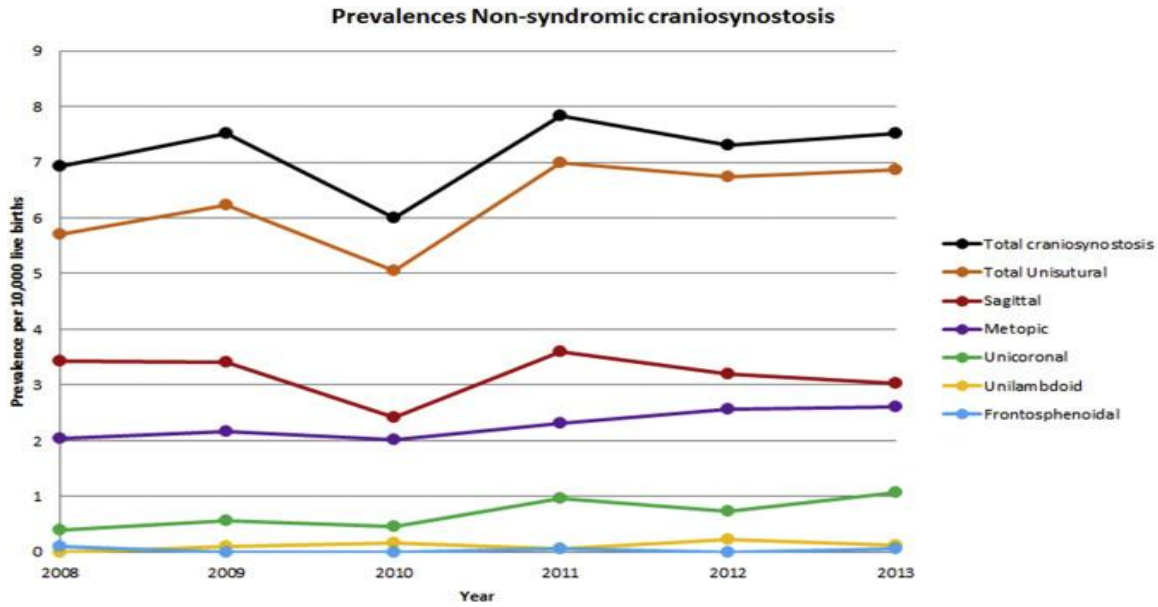
Table No. 2: Clinical picture and complications of patient

Craniosynostosis	Sagittal		Metopic		Unicoronal		Multiple*		Total	
	Abs	%	Abs	%	Abs	%	Abs	%	Abs	%
Syndromic	15	17	18	20	18	20	38	43	89	100
Apert	0		0		1		11		12	
Muenke	0		0		4		7		11	
Crouzon/Pfeiffer	1		0		0		6		7	
Saethre-Chotzen	0		0		6		3		9	
Rare syndrome	4		5		5		6		20	
Unknown	10		13		2		5		30	
Nonsyndromic	147	62	60	25	19	8	13	5	239	100
Total	162	49	78	24	37	11	51	16	328	100

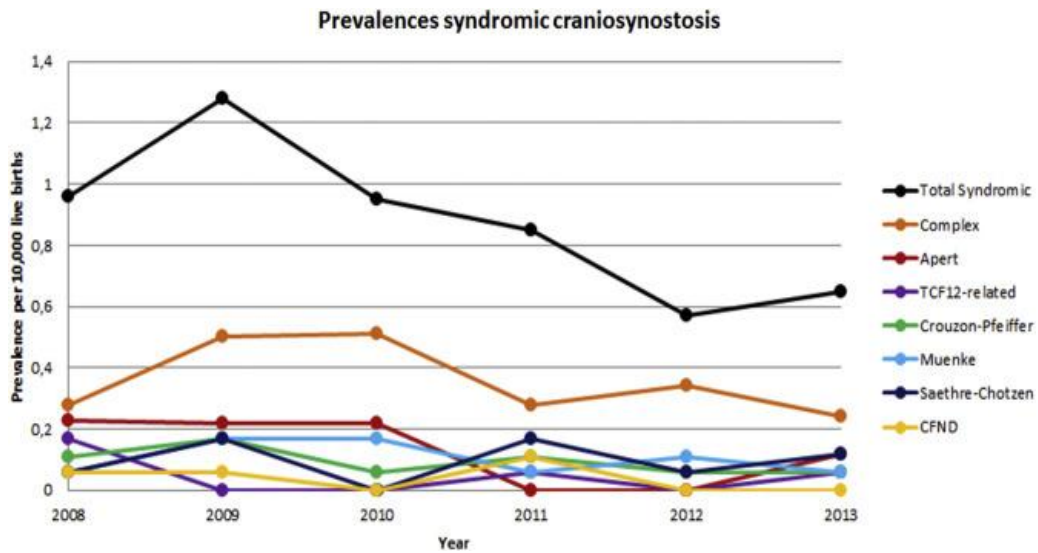
* Multiple synostosis including bicoronal synostosis.



Graphical description:-Median age (in days - Y- axis) at diagnosis for syndromic and nonsyndromic craniosynostosis, 2003- 2017



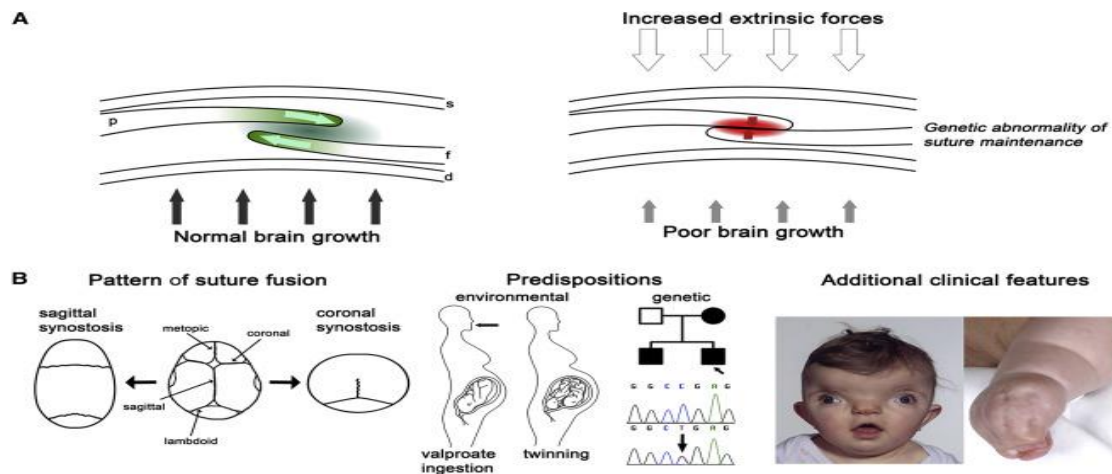
Graph no. 1: Increase of prevalence of non syndromic craniosynostosis



Graph No. 2: Prevalence of syndromic craniosynostosis

Between 2008 and 2013 759 patients with craniosynostosis were born in the Netherlands. Prevalence of craniosynostosis was 7.2 per 10.000 live births. Sagittal synostosis was the most common form (44%). Poisson regression analysis showed a significant mean annual increase of prevalence of total craniosynostosis (+12.5%), sagittal (+11.7%) and metopic (+20.5%) synostosis from 1997 to 2013.

CLINICAL PRESENTATIONS: The specific deformity of skull is kleeblattschdel or cloverleaf includes:



• **Table No. 3 :** A genetic pathophysiological framework for craniosynostosis

Normal sutures: include the metopic (m), coronal (c), sagittal (s), lambdoid (l), and squamosal (sq). In craniosynostosis, the anterior fontanel (af), or “soft Spot,” may be open or closed.

Diagnosis:

Crouzon syndrome is usually diagnosed at birth during infancy. The diagnosis of Crouzon syndrome is based upon a thorough clinical evaluation, identification of characteristic physical findings and a variety of tests.

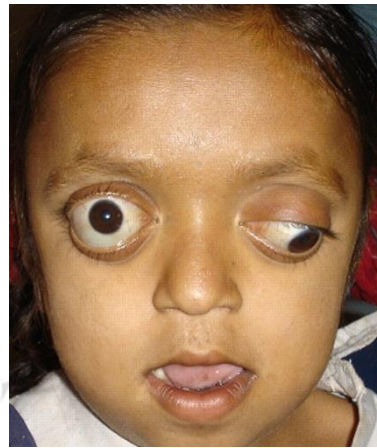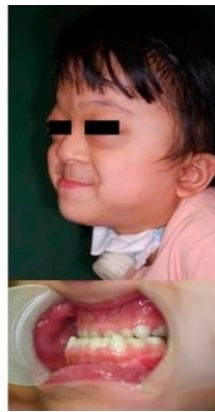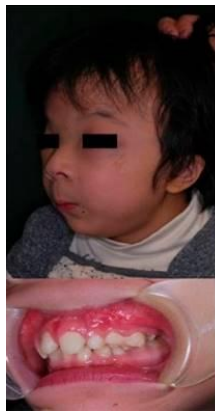The diagnosis of crouzon syndrome is done by the following:-

1. physical examination
2. Radiography
3. MRI scanning
4. Genetic testing
5. X-ray
6. CT scan

1. Physical examination:- This is the first step in the diagnosis of crouzon syndrome. This includes phenotypic features like:-

- Craniosynostosis (2or more fibrous joints in a baby’s skull join together prematurely)

- Shallow orbits and reduced depth of orbits.
- Ocular proptosis.
- Sudden protrusion of the eye from its socket.
- Eutropia is very common.
- Blindness and poor vision in some cases
- Conductive hearing deficit
- Pointed nose.
- Dental abnormalities.

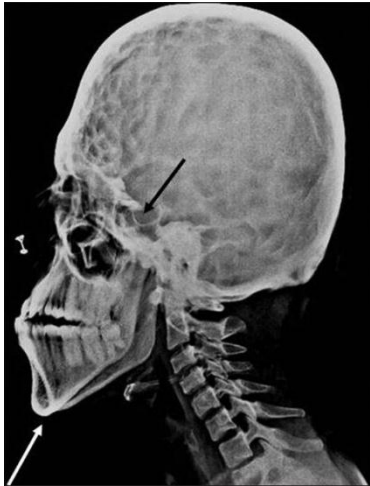


Dental abnormalities.

protrusion of the eyeball from its socket.

2. RADIOGRAPHY:- It is a non-destructive examination (NDE) technique that involves the use of either x-rays or gamma rays to view the internal structure of a component.

This radiography is of four types. They are computed radiography(CR),direct radiography(DR),real-time radiography(RTR),computed tomography (CT).



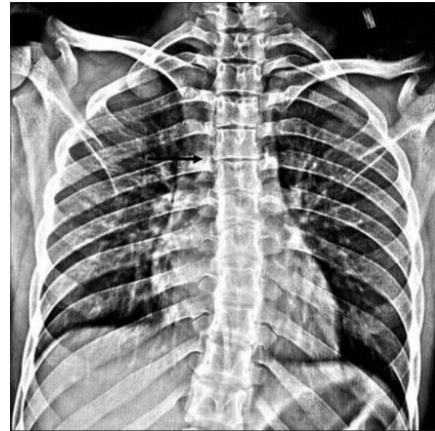lateral skull projection.

(mandibular prognathism(white arrow)

Maxillary hypoplasia, copper beaten.

Appearance, and enlarged hypophyseal.

Cavity(black arrow)

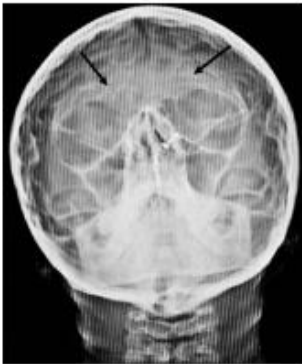

Anterior-posterior spine radiograph

(shows decreased intervertebrally

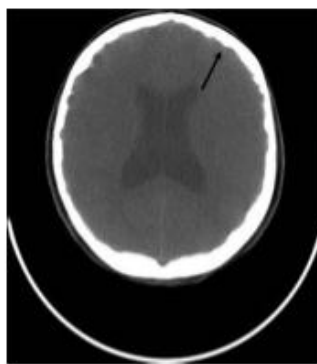
Space between C5 and C6 (black

Arrow)).

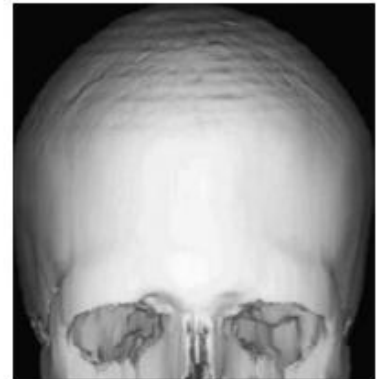


Paranasal sinus.

(prominent convolution)



Computed tomography



3-D computed tomography

(shows increased
Circumference of a skull)

3. MRI scanning:- It is a medical imaging technique used in radiology to form pictures of the anatomy and the physiological processes of the body. MRI is accurate in the detection of associated brain abnormalities, which is an important prognostic issue in this diagnosis. When synostosis is suspected on ultrasonography the prenatal MRI is suggested.

4. Genetic testing:-It can be done by using a sample of blood or saliva. It can detect mutations in the FGFR2 gene known to cause disease.

FGFR2- fibroblasts growth factor receptor 2

Table 4

FGFR2- Associated Craniosynostotic Syndromes

Syndrome	Inheritance	Mutations	Craniosynostosis Findings	Extracranial Phenotypes	Ref.
Crouzon Syndrome		Cys278Phe, Trp289Gly, Tyr290Gly, Ser267Pro, Tyr328Cys, Gly338Arg, Tyr340His, Cys342Tyr, Cys342Arg, Cys342Phe, Cys342Ser, Cys342Trp, Ala344Gly, Asn549Thr, Ser347Cys, Ser354Cys	Bicoronal synostosis, pansynostosis late	Crouzonoid face (flattened forehead, proptosis, hypertelorism, beaked nose, midface hypoplasia), normal hands	[35, 51,54-56,61

Genetic testing is a type of medical test that identifies changes in chromosomes, genes, or proteins. The results of genetic testing can confirm or rule out a suspected genetic condition or help to determine a person's chance of developing or passing on a genetic disorder. More than 1,000 genetic tests are currently in use, and more are being developed.

Several methods can be used for genetic testing.

The following are types of genetic testing:-1.molecular genetic testing

2. Chromosomal genetic testing

3. Biochemical genetic testing.

Molecular genetic testing /gene tests	Chromosomal genetic testing	Biochemical gene testing
It studies single genes/short lengths of DNA to identify variations or mutations that lead to a genetic disorder	It analyses the whole chromosomes or long lengths of DNA to see if there are large genetic changes, such as an extra copy of a chromosome that causes genetic condition	It studies the amount or activity level of proteins, abnormalities in either can indicate changes to the DNA that result to genetic disorders.

-genetic testing is voluntary. Because testing has benefits as well as limitations and risks, the decision about whether to be tested is a personal and complex one.

5. X-RAY:- It is a diagnostic test that uses invisible electromagnetic energy Beams to produce images of internal tissues, bones and organs onto film. These use invisible electromagnetic energy beams to produce images. When the body undergoes X-rays, different parts of the body allow varying amounts of the x-ray beams to pass through.

Radiation during pregnancy is used to detect birth defects like Croydon syndrome and other genetic diseases etc.

6. CT SCAN:- It is a non-invasive diagnostic imaging procedure that uses a combination of special x-ray equipment and sophisticated computer technology to produce cross-sectional images (often called slices), both horizontally and vertically, of the body. These images of the area being studied can then be examined on a computer monitor or printed.

In this syndrome the following are observed through CT scan:-

- premature closure of Saturday suture in its posterior aspect.
- hydrocephalous (fluid filled ventricles in the brain)

CT scan is more detailed than that of general x-rays. In this x-ray beam moves in a circle around the body. This allows many different views of the same organ or structure .X – ray information is sent to a computer and that interprets the X-ray data and displays it in a 2D form of a monitor.

TREATMENT:-

Goals of treatment:-

- To allow the increase in size of the skull to make room for the growing brain and to restore a normal head shape.
- To relieve pain inside the skull.
- To fix a cleft lip or palate.
- To correct a malformed jaw.
- To straighten crooked teeth.
- To correct eye problems.

Early diagnosis is very important in this case. In first year of baby, it is preferred to release synostotic sutures of skull to allow adequate brain development. Repeated surgery is needed to obtain better results. If necessary, mid-facial advancement and jaw surgery are to be done, to provide adequate orbital volume and decrease in the exophthalmoses to correct the occlusion to an appropriate function, position and to provide more normal appearances. After surgery bone will grow in their natural process along the coronal plane.

People with crouzon's syndrome have a normal life expectancy. Most children with this condition are unaffected intellectually, however, can alter the shape of the face and cause vision and hearing problems. Signs can start in the first few months of baby's life and continue to progress until she or he comes to an age of 2 or 3 years.

Children with mild may need not to be treated. Those with more severe cases should see doctors who are specialized in craniofacial (who treats disorders of skull and face). In more severe cases, doctors can perform surgery to open up the suture and give the brain to grow.

In some cases, the neurosurgeon will suggest strip craniotomy surgery.

Strip craniotomy:-A section of skull, shaped like Greek letter pie(π) was removed.

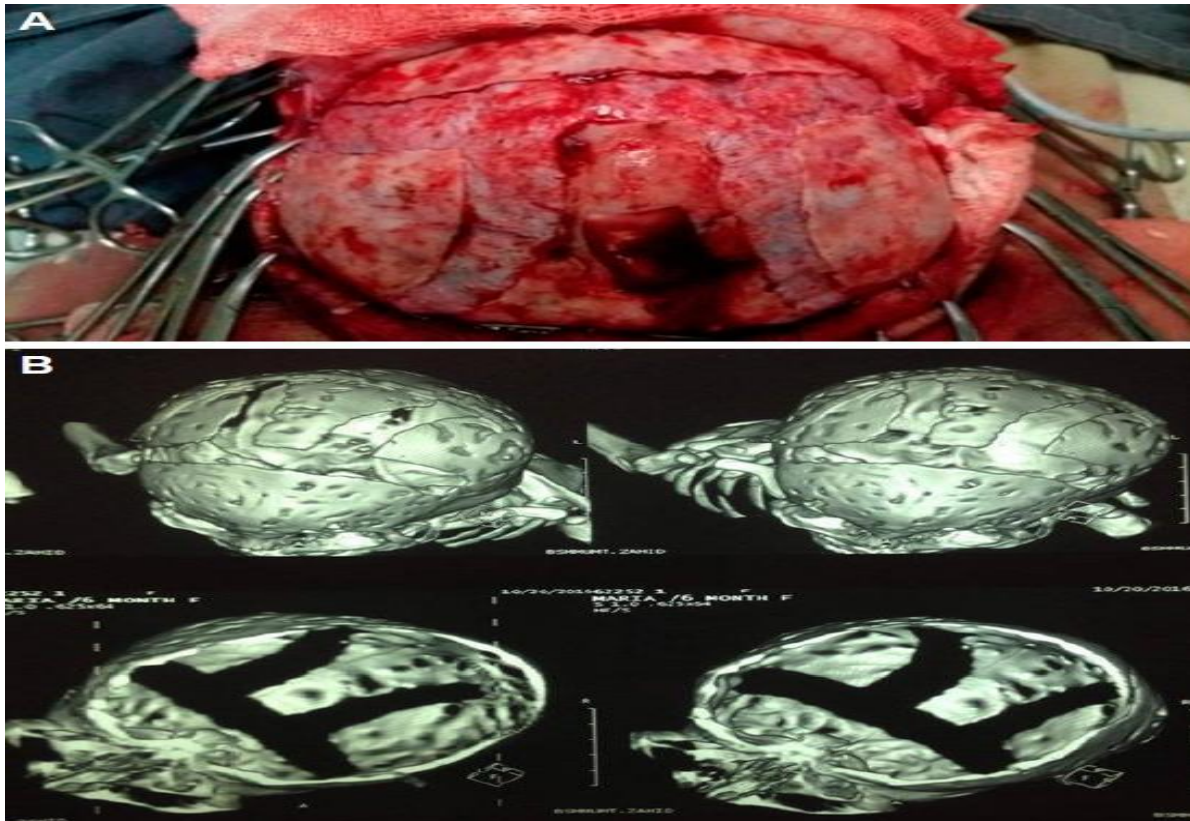


Fig. (A) pre-operative view

(B) postoperative view computed tomography scan showing pie(π) procedure done in a six months old baby.

After surgery, the patient should be on IV antibiotics and if the stable child can be discharged and follow up for 21 days with medication. If childless is stable with normal laboratory reports after 21 days, then the child becomes normal.

After surgery, kids will need to wear a special helmet for a few months to reshape their skull. Child with hearing problems can wear hearing aids to amplify sounds. Kids with this condition may also need speech and language therapy. After surgery, bone will grow in their natural process along the coronal panel.

REFERENCES:

1. <https://www.ncbi.nlm.nih.gov/pmc/articles/PMC3060331/>
2. <https://www.medicalnewstoday.com/articles/223128>
3. <https://emedicine.medscape.com/article/1281182-overview#a1>
4. <https://www.nationwidechildrens.org/conditions/craniosynostosis>
5. <https://www.mayoclinic.org/diseases-conditions/craniosynostosis/symptomscauses/syc-20354513>
6. <https://www.cdc.gov/ncbddd/birthdefects/craniosynostosis.html#:~:text=What%20is%20Craniosynostosis%3F,Craniosynostosis%20is%20a%20birth%20defect%20in%20which%20the%20bones%20in,flexible%20material%20and%20called%20sutures.>
7. <https://pubmed.ncbi.nlm.nih.gov/27499511/>
8. https://www.researchgate.net/publication/340436481_Epidemiology_of_craniosynostosis_in_Norway
9. <https://emedicine.medscape.com/article/1175957-clinical#:~:text=The%20specific%20deformity%20of%20the,papilledema%2C%20vomiting%2C%20and%20lethargy.>
10. <https://www.ncbi.nlm.nih.gov/pmc/articles/PMC5988529/>
11. <https://www.seattlechildrens.org/conditions/craniosynostosis/#:~:text=The%20main%20treatment%20for%20craniosynostosis,of%20pressure%20on%20the%20brain.>
12. <https://academic.oup.com/hmg/article/15/8/1319/644564>
13. <https://rarediseases.org/rare-diseases/crouzon-syndrome/>
14. <https://www.healthline.com/health/crouzon-syndrome#causes>
15. <https://www.medicalnewstoday.com/articles/321605#prevention>
16. <https://www.slideshare.net/mobile/srvmalhotra1/crouzon-syndrome-62069536>
17. <https://emedicine.medscape.com/article/942989-clinical#b2>
18. <https://www.ncbi.nlm.nih.gov/pmc/articles/PMC3551519/>
19. <https://www.ncbi.nlm.nih.gov/pmc/articles/PMC5723914/#!po=10.7477>

	<p>Sagarla Hema, 4th year pharm D, Pulla Reddy institute of pharmacy.</p>
	<p>Kathi Sandhya, 4th year pharm D, Pulla Reddy institute of pharmacy.</p>
	<p> <i>Dunaboina Poojitha Sangavi,</i> <i>4th year pharm D, Pulla Reddy institute of pharmacy.</i></p>