



IJSRM

INTERNATIONAL JOURNAL OF SCIENCE AND RESEARCH METHODOLOGY

An Official Publication of Human Journals



Human Journals

Research Article

November 2020 Vol.:17, Issue:1

© All rights are reserved by S. Anitha et al.

Red and Near-Infrared Light-Induced Photobiomodulation Therapy on Wound Healing Among Patients with Diabetic Foot Ulcers: A Quasi Experimental Study



S. Anitha*¹, A. Felicia Chitra²

¹M.Sc. Nursing student, Department of Medical Surgical Nursing, Mother Theresa Post Graduate and Research Institute of Health Sciences, Pondicherry University, Puducherry, India.

²Principal, College of Nursing, Department of Medical Surgical Nursing, Mother Theresa Post Graduate and Research Institute of Health Sciences, Pondicherry University, Puducherry, India.

Submission: 25 October 2020

Accepted: 31 October 2020

Published: 30 November 2020



HUMAN JOURNALS

www.ijsrm.humanjournals.com

Keywords: Diabetic foot ulcer, Photobiomodulation, Low level light therapy, wound healing

ABSTRACT

Background: Photobiomodulation Therapy also called as Low Level Light Therapy is the application of biostimulative light energy to the body cells that strengthens the mitochondria and increases the ATP production, thereby accelerating the wound healing process. The aim of this study was to assess the existing level of wound status, to evaluate the effectiveness of Red and Near-Infrared Light-Induced Photobiomodulation Therapy on wound, to correlate the size of ulcer with the wound status and to associate the level of wound status with their selected demographic and clinical variables. **Materials and methods:** A total of 60 patients who had fulfilled the inclusion criteria were selected and assigned randomly to the Experimental and Control group. The patients in the Experimental group received Red and Near-Infrared Light-Induced Photobiomodulation Therapy (Red light-660nm; Near-Infrared-980nm) while the patients in the Control group received conventional therapy for a period of 15 days. Assessment of the wound status was done on day 1 and day 15. **Results and conclusion:** The results predicted that the intervention has worked towards reducing the size of ulcer by an average of 4.5cm² as well as improving the wound status by decreasing the mean total score by an average of 12.250 in the Experimental group. Hence, the intervention was found to be effective in speeding up the wound healing process among patients with DFUs.

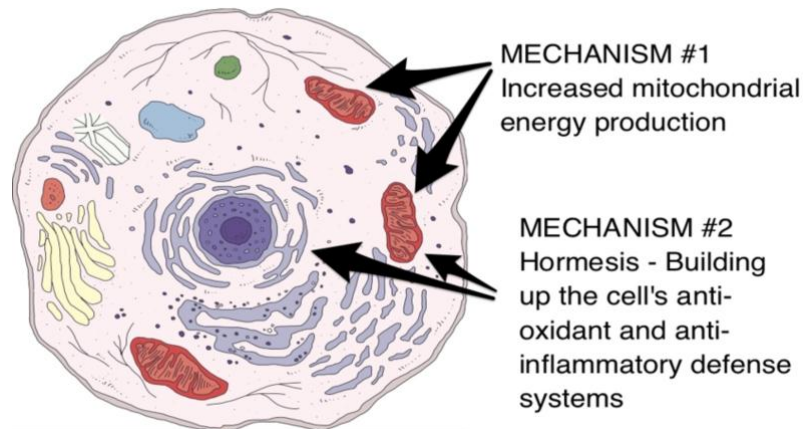
1. INTRODUCTION

Diabetes Mellitus is a group of metabolic diseases characterized by hyperglycaemia resulting from defects in the secretion and/or action of insulin produced by the pancreas. The International Diabetes Federation states that there is over 72.946.400 cases of Diabetes in India in 2017 [1]. Diabetic Foot Ulcers (DFUs) are the most common complication of Diabetes Mellitus. It can be defined as a neuropathic complication that causes biomechanical alterations on the distal extremity, frequently on toes, on the lateral faces of the interdigital compression zones, and the lateral edges of the feet [2]. **P Ghosh and R Valia (2017)** expressed that in India, DFUs affect 15% of diabetics during their lifetime. Out of the 69 million cases of Diabetes, 25% develop DFUs of which 50% get infected and 20% require amputation. DFUs contribute to approximately 80% of all non-traumatic amputations in India, annually [3]. Diabetes Mellitus can end up in a variety of complications such as peripheral neuropathy, hypertension, hyperlipidemia, and mild macular degeneration [4].

Unfortunately, DFUs can endanger the life of thousands of patients and affects the patient's day-to-day activities. The patients with DFUs are more likely to have depression and anxiety compared to diabetic patients without a foot ulcer [5]. In addition to depression, the patients with DFUs also experience decreased role performance in their family as well as among the workgroups. According to a newspaper article published in **The Times of India (2013)**, patients with DFUs have a high risk of death compared to diabetic patients without a foot ulcer. It has been given that there were an additional 58 deaths per 1000 deaths, each year of patients with DFUs. DFUs doubles the death rate and cardiovascular problems while it increases the risk of stroke by 40% [6].

Photobiomodulation Therapy also called as Low Level Light Therapy or Low Level Laser Therapy (LLLT) is the application of biostimulative light energy to the body cells. Photobiomodulation therapy works by producing a biochemical effect on the cells that strengthens the mitochondria [7]. This leads to increased adenosine triphosphate (ATP) production, modulation of reactive oxygen species and induction of transcription factors. These in turn lead to increased cell proliferation, migration and increased tissue oxygenation.

TWO KEY MECHANISMS OF RED/NIR LIGHT THERAPY



Source: *The energy blueprint*, 2020

Figure No.1: Mechanism of Red and Near-Infrared Light-Induced Photobiomodulation Therapy

The biochemical mechanism behind light therapy resides in the absorption of light by the chromophores or the photoacceptors that are present in the molecular, cellular, and tissue levels, that results in cellular changes including the synthesis of collagen and other extracellular matrix which aids in the wound healing process. LLLT mainly depends on the absorption properties of the skin, device characteristics (wavelength, power density, irradiation time and the treatment protocol), frequency of the treatment and the treatment intervention time [8].

In spite of substantial numbers of emerging technologies of potential value in the treatment of chronic wounds, there is also an urgent need to increase the quality of clinical studies. **Fonseca Santos et al. (2018)** also asserted that LLLT has been proven to be effective in reducing the necessary time for the tissue repair process in ulcers on a diabetic foot over a short time period [9].

The use of Photobiomodulation Therapy is being supported by the researcher as it enhances the wound healing process and thus prevents the amputation of extremity due to DFU. Also, this therapy can help in decreasing the amount of wound exudate which reduces the odour. This provides chances for the patient to improve their self-esteem, overcome depression and prevent thoughts of suicide. Therefore, the present study was conducted to assess the existing level of

wound status, to evaluate the effectiveness of Red and Near-Infrared Light-Induced Photobiomodulation Therapy on wound healing, to correlate the size of ulcer with the wound status and to associate the level of wound status with their selected demographic and clinical variables.

2. MATERIALS AND METHODS

2.1. Study Design

A Quasi-Experimental study adopting Nonrandomized Control group design was conducted at the outpatient departments of selected Primary Health Centres and Community Health Centres in Puducherry, India. The study was conducted for a period of 30 days from 04/11/2019 to 03/12/2019.

2.2. Study Participants

The study participants included the patients with DFU attending the outpatient departments of selected Primary Health Centres and Community Health Centres. A total of 60 patients who had fulfilled the inclusion criteria were randomly selected and assigned to the Experimental and Control group. A standardized tool, called Bates Jensen Wound Assessment Tool (BWAT), was used in the research study to assess the level of Wound Status. Approval, ethical clearance and a written informed consent was obtained.

2.3. Data Collection

In order to carry out the intervention, the patient was provided privacy and placed in a comfortable position with the wound exposed. Pretest assessment of the wound status was done using Bates Jensen Wound Assessment Tool. The wound was then cleaned with normal saline, hydrogen peroxide, betadiene solution and was wrapped with a thin plastic material so as to prevent cross infection when using on another patient. The light pads with alternative rows of Near-Infrared (980nm wavelength) and Red LEDs (660nm wavelength) were attached to the patient's feet in direct contact. The timer was set in the device and mode has been selected. Once the set time has been reached, the device shuts off immediately. The therapy was administered for 15 consecutive sessions with 20 minutes daily.

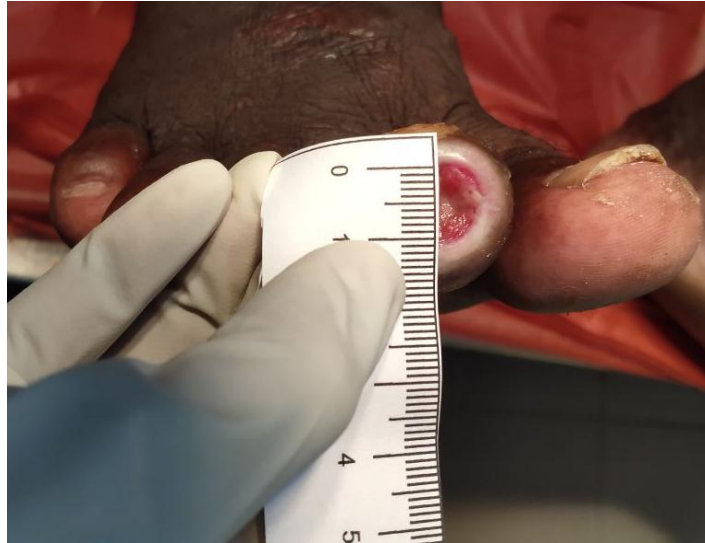

Figure No. 2: Measurement of the wound size

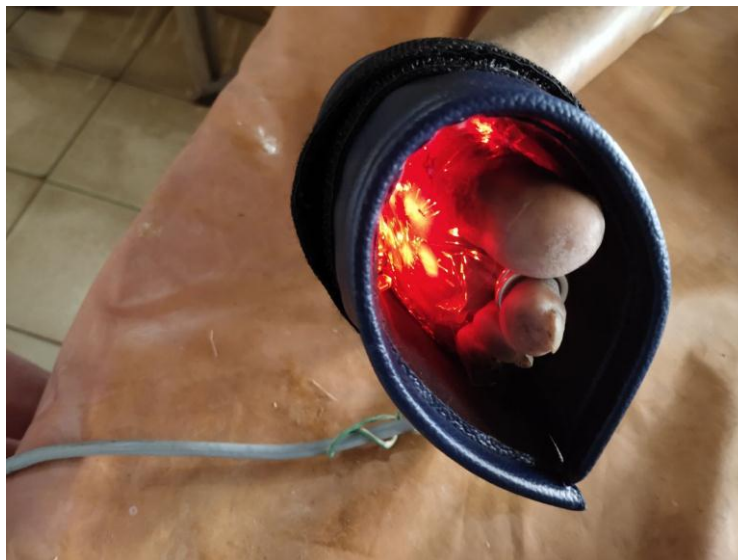


Figure No. 3: Light pads attached to the wound surface

The patients assigned to the Control group received regular conventional treatment as prescribed by the Physician (daily cleaning and dressing). On day 15, the Post Test level of wound status was assessed using Bates Jensen Wound Assessment Tool. The collected data was analyzed by using descriptive and inferential statistics.

RESULTS AND DISCUSSION

In order to distinguish between the groups, chi-square test was carried out between the pretest levels of wound status. The non-significant 'p' value (0.696) at $p < 0.05$ level indicated that there was no significant difference in the level of wound status between the Experimental and Control group before the intervention, which means that both the groups were homogenous prior to the intervention. A similar study conducted by **Hakim, et al (2016)**, illustrated that the mean score in the Experimental group before the intervention was 230.2 (maximum score is 400 with higher scores indicating higher healing) and in the Control group, it was 196.92 with a mean difference of 33.28. These showed no significant difference between the two groups before the intervention [10].

From Figure 3, it can be observed that after a period of therapeutic intervention using Red and Near-Infrared Light-Induced Photobiomodulation Therapy, there was an improvement in the wound status with reduction of the score in the Experimental group.

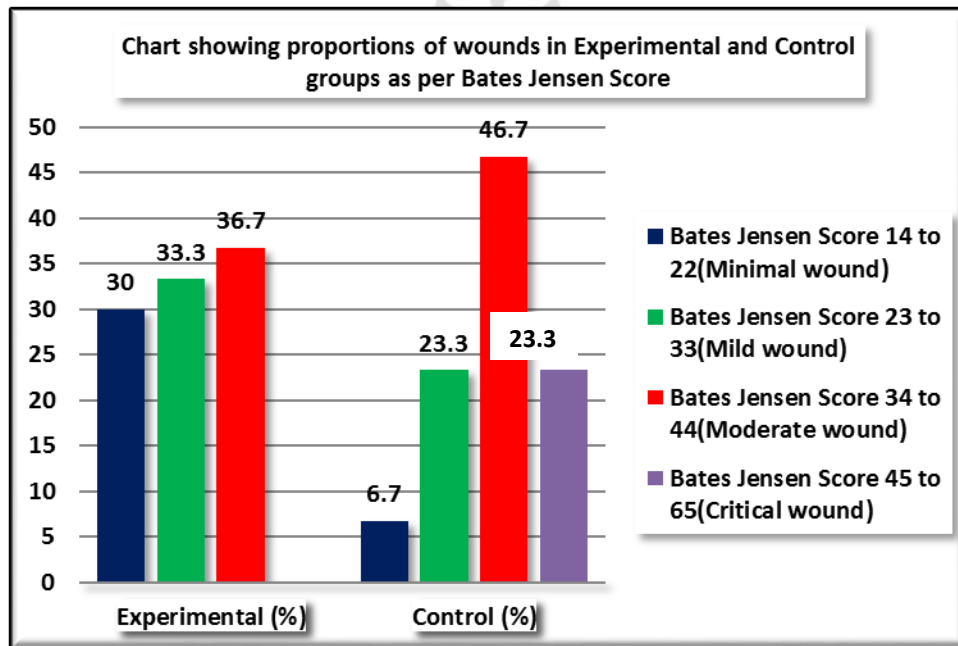


Figure No. 4: Distribution of patients with Diabetic Foot Ulcers in Experimental and Control group based on Post Test Level of Wound Status

TABLE No. 1: Comparison of Size of Ulcer between Pretest and Post Test among patients with Diabetic Foot Ulcer in the Experimental and the Control group N=60

Group	Size of Ulcer	Mean	SD	Paired 't' Test value	Mean difference	95%CI of mean diff	
						Lower	Upper
Experimental (n=30)	Pretest	25.314	36.1708	t=20.031 p<0.001 S***	4.5459	2.3333	6.7584
	Post Test	20.768	34.3861				
Control (n=30)	Pretest	25.791	36.6940	t=1.031 p=0.087 NS	0.8069	-.1247	1.7385
	Post Test	24.984	36.9721				

***p<0.001, S-Significant NS-Not Significant at p<0.05

The results also denoted that within individual Experimental group, there was a highly statistically significant 't' test value of 20.031 at p<0.001 level, with a mean difference of 4.5cm² in the Size of Ulcer between Pretest and Post Test. Whereas, in the Control group, the 't' test value was not statistically significant and the mean difference in the size of ulcer was only 0.8cm². Hence, the intervention was proven to be effective in reducing the size of ulcer by 4.5cm².

Priyadarshini et al (2018) conducted a similar study and found that the mean area of the ulcer was 3.97±5.41 during Post Test in the Experimental group, whereas it was 18.80±17.70 in the Control group. The mean changes in area was 9.77±7.83 in the Experimental group and 0.28±11.37 in Control group. It was found to be statistically significant at P<0.001 level [11].

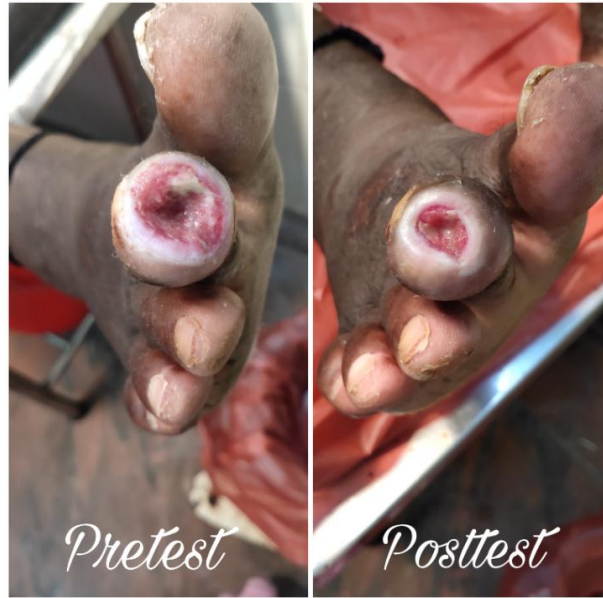

Figure No. 5: Foot ulcer before and after the intervention

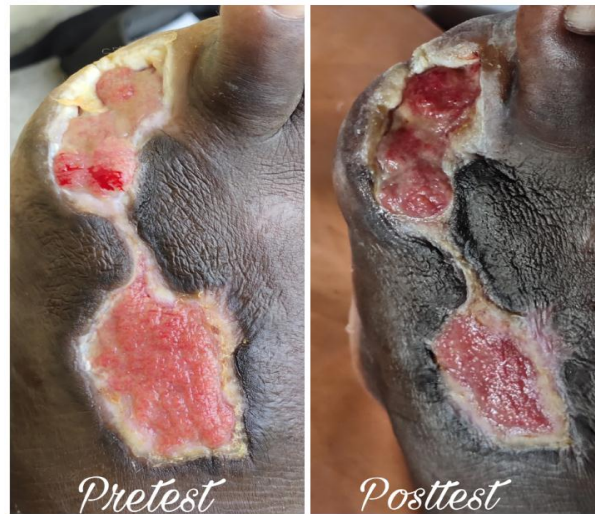

Figure No. 6: Foot ulcer before and after the intervention

Also, there was a statistically significant difference in the wound status between the Pre and Post Test of the Experimental and Control group with a mean difference of 12.250 at $p < 0.001$ level and 1.9310 at $p < 0.005$ level respectively. Hence, the intervention was also proven to be effective in reducing the mean total score in the Experimental group by 12.250. These results are supported by a similar study conducted by Santos, et al (2018) which proved that there was a significant increase in the tissue repair index after the therapy in the Experimental group compared to the Control group with a significant statistical difference ($P < 0.013$) [12].

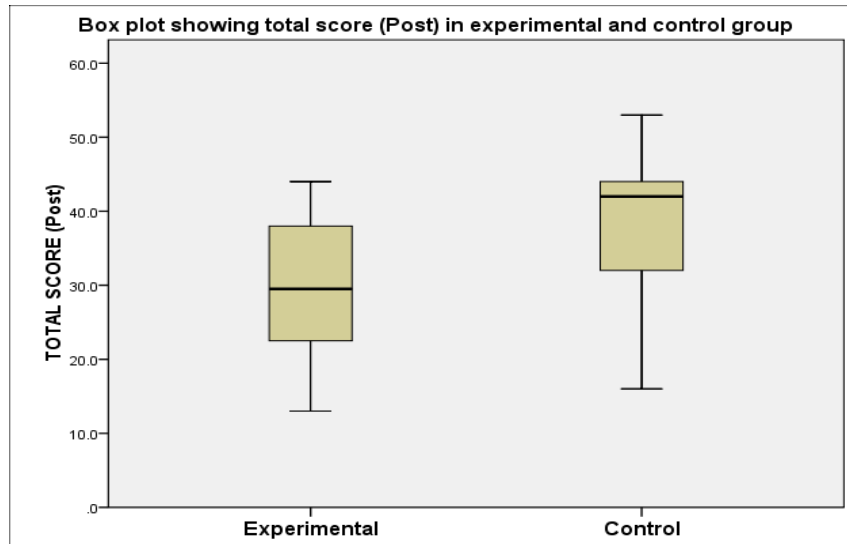


Figure No. 7: Box plot showing mean of Post Test wound status among patients with Diabetic Foot Ulcer in the Experimental and Control group

The results also revealed that there was a positive correlation between the Post Test size of ulcer and the wound status in the Experimental group with the Pearson correlation r-value of 0.285 at $p=0.142$ which was not significant. The demographic variable residence had shown statistically significant association between the Post Test Level of Wound Status at $p < 0.001$ level.

CONCLUSION

Patients with Diabetic Foot Ulcers often have problems with healing of the ulcer. It takes their whole lifetime for an ulcer to heal completely. This therapy promotes cellular growth and hence quickens the wound healing process. Also, this therapy has the advantage of being easily administered and also produces no side effects in the patients. Based on the results, it's proven that there was a statistically significant difference in the wound status after Red and Near-Infrared Light-Induced Photobiomodulation Therapy. Therefore, it can be concluded that Red and Near-Infrared Light-Induced Photobiomodulation Therapy helps in improving the process of wound healing in patients with diabetic foot ulcers.

REFERENCES

[1] International Diabetes Federation. South East Asia Members [online]. 2017 [cited 2019 October 13]. Available from: <https://idf.org/our-network/regions-members/south-east-asia/members/94-india.html>

- [2] Mckean. Orthobullets. Diabetic foot ulcers [online]. 2019 [cited 2020 September 20]. Available from: <https://www.orthobullets.com/foot-and-ankle/7046/diabetic-foot-ulcers>
- [3] P Ghosh, R Valia. Burden of Diabetic Foot Ulcers in India: Evidence Landscape from Published Literature. Value in Health. 2017; 20(9):A485.
- [4] Diabetes. World Health Organization [online]. [Cited 2019 September 25]. Available from: https://www.who.int/health-topics/diabetes#tab=tab_1
- [5] Ahmad, et al. Anxiety and depression among adult patients with diabetic foot: prevalence and associated factors. Journal of Clinical Medicine Research. 2018; 10(5): 411–418.
- [6] Times of India. Diabetic foot ulcers double death rate: Study [online]. 2019. Available from: <https://timesofindia.indiatimes.com/city/ahmedabad/Diabetic-foot-ulcers-double-death-rate-Study/articleshow/25783943.cms>
- [7] Denise Hawkins, Heidi Abrahamse. Phototherapy-a treatment modality for wound healing and pain relief. African Journal of Biomedical Research. 2007; 10:99-109.
- [8] Photobiology. Mechanisms of low level light therapy [html]. 2005 [cited October 14]. Available from: <http://photobiology.info/Hamblin.html>
- [9] Feitosa, et al. Effects of low-power light therapy on the tissue repair process of chronic wounds in diabetic feet. Photomedicine and Laser Surgery. 2015; 36(6):298-304.
- [10] Hakim, et al. Effect of Infrared Radiation on the Healing of Diabetic Foot Ulcer. International Journal of Endocrinology and Metabolism. 2015; 14(3), e32444.
- [11] Priyadharshini LMJ, et al. Effect of low level laser therapy on diabetic foot ulcers: a randomized control trial. International Surgery Journal. 2018; 5(3), 1008-1015.
- [12] Santos, J, et al. Effects of low-power light therapy on the tissue repair process of chronic wounds in diabetic feet. Photo medicine and Laser Surgery. 2018; 36(6), 298-304.

<p><i>Image</i></p> <p><i>Author -1</i></p>	<p>Ms. S. Anitha</p> <p><i>Author Affiliation-</i> Pondicherry University</p> <p><i>Author Address/Institute Address-</i> Mother Theresa Post Graduate and Research Institute of Health Sciences, Pondicherry University, Puducherry, India.</p>
<p><i>Image</i></p> <p><i>Author -2</i></p>	<p>Prof. Dr. A. Felicia Chitra - <i>Corresponding Author</i></p> <p><i>Author Affiliation-</i> Pondicherry University</p> <p><i>Author Address/Institute Address-</i> Mother Theresa Post Graduate and Research Institute of Health Sciences, Pondicherry University, Puducherry, India.</p>