



# IJSRM

INTERNATIONAL JOURNAL OF SCIENCE AND RESEARCH METHODOLOGY

An Official Publication of Human Journals



Human Journals

## Case Report

April 2018 Vol.:9, Issue:2

© All rights are reserved by Bassem Abou Merhi et al.

# Intestinal Perforation Caused by Shigella Infection - A Rare Case Report



## IJSRM

INTERNATIONAL JOURNAL OF SCIENCE AND RESEARCH METHODOLOGY

An Official Publication of Human Journals



**Rami Harb<sup>2</sup>, Hala Saneh<sup>1</sup>, Bassem Abou Merhi\*<sup>1</sup>,  
Christine Hakme<sup>4</sup>, Hanin Jouni<sup>1</sup>, Hicham Dabaja<sup>1</sup>,  
Sally Slim<sup>1</sup>, Nabil Diab<sup>3</sup>, Saliba Saba<sup>2</sup>, Rima  
Hazzouri<sup>1</sup>, Suzi Mansour<sup>1</sup>**

1. *Department of Pediatrics. Lebanese University, Faculty of Medical Sciences.*
2. *Department of General Surgery. Lebanese University, Faculty of Medical Sciences.*
3. *Department of Pediatric Surgery. Balamand University.*
4. *Department of Pediatrics. Saint Charles Hospital.*

**Submission:** 20 March 2018

**Accepted:** 27 March 2018

**Published:** 30 April 2018



HUMAN JOURNALS

[www.ijsrm.humanjournals.com](http://www.ijsrm.humanjournals.com)

**Keywords:** Shigella specious, Intestinal Complication, Intestinal Perforation

## ABSTRACT

Shigella specious is a common pathogen responsible for bacterial gastroenteritis worldwide, mainly in developing countries. The typical clinical presentation consists of high grade fever, abdominal cramps and bloody mucoid diarrhea. However, the spectrum of severity may vary from mild diarrhea to severe dysenteric symptoms, intestinal and systemic complications. We present here the case of a 5-year-old previously healthy girl who was hospitalized for fever, crampy abdominal pain, vomiting and diarrhea. Physical examination revealed first a soft abdomen, diffusely tender on palpation. However, on the second day of hospitalization, the patient developed tachypnea and hypoactivity with worsening abdominal pain. Air under the diaphragm was found on abdominal radiographs, and CT abdomen confirmed the presence of a pneumoperitoneum. The patient completely recovered without any additional complications. Intestinal perforation is one of the extremely rare complications of Shigellosis, especially beyond infancy. An early diagnosis could help prevent Shigella complications if the treatment is initiated early in the course of the disease.

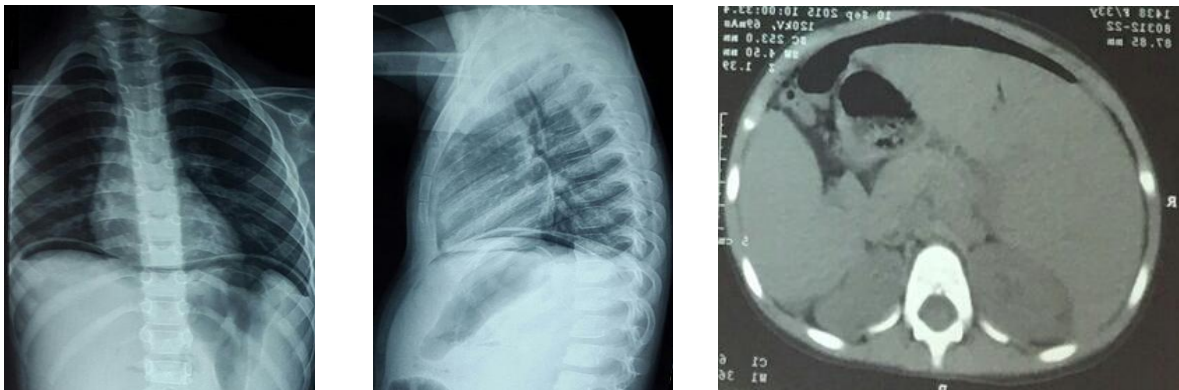
## INTRODUCTION

Shigella is a gram-negative bacillus of the Enterobacteriaceae family. Four species with more than 40 serotypes have been identified. Shigellosis commonly occurs in children worldwide, and mainly in overcrowded areas with poor sanitation (1). The severity of the disease varies with the age group and depends on the serotype of the infecting pathogen. Symptoms may be limited to a simple watery diarrhea, while some serotypes may cause severe dysenteric symptoms, including high-grade fever, abdominal cramps and bloody diarrhea (2). Tenesmus is also a common complaint in children. Several intestinal and extra-intestinal systemic complications may occur in the setting of a Shigella infection; however, these are relatively rare (3), and are unusual to be the primary manifestation of the disease.

### Case Report:

A 5 year old girl, previously healthy, presented to the emergency department for 4 days history of fever (increasing gradually with time and reaching 40°C), associated with severe watery non bloody diarrhea, crampy abdominal pain and non-bilious non-projectile vomiting. The mother and the older sister of the patient were having similar symptoms of fever, abdominal pain and diarrhea: the mother was being treated at home with broad-spectrum antibiotics for suspected bacterial infection, and the sister was hospitalized for intravenous hydration and management. At presentation, the patient was febrile of 39°C and tachycardic at 180 beats per minute; her vital signs were otherwise normal. Physical examination revealed a soft nondistended abdomen, diffusely tender on deep palpation. Laboratory tests showed a normal WBC count of 7430 per microliter with 85% neutrophils, a hemoglobin level of 10.8g/dL, and a slightly low platelet count of 108000 per microliter. CRP was elevated at 219 (normal reference value <5 mg/L). Urea, creatinine and electrolytes were all normal. Wright and Widal tests were negative. Blood and stool cultures were taken. Patient was hospitalized and started to receive intravenous hydration. The next day, she was still having high grade fever (reaching 40°C, not spacing) with worsening abdominal pain. She became also hypoactive and started to develop tachypnea with normal oxygen saturation on room air; her blood pressure was maintained at around 90/50 mmHg. Repeated laboratory tests showed a WBC count of 6720 per microliter with 82% neutrophils and a decreasing platelet count to 79000 per microliter. INR was slightly prolonged at 1.55, PTT was normal of 42. Fibrinogen level was 423 mg/dL and CRP increased within 24 hours to 354 mg/L. KUB, done urgently, showed air under the diaphragm with distention of the small intestine.

Abdominal CT scan revealed a pneumoperitoneum with mild ascites, dilatation of small intestinal loops and normal appendix (Figure 1).



**Figure 1: AP and lateral radiographs done on the second day of hospitalization. Air under the diaphragm suggestive of pneumoperitoneum is seen. Pneumoperitoneum is also evident on abdominal CT.**

The patient was immediately started on broad-spectrum antibiotics for intestinal perforation and DIC: intravenous Ceftriaxone, Amikacin and Metronidazole. Urgent laparotomy was done to identify and treat the cause of the pneumoperitoneum. Two ulcers were found on the anterior mesenteric side of the ileum: at 10 cm and at 20 cm from the ileocecal valve. So the patient underwent resection of 10 centimeters of the distal ileum with end-to-end anastomosis and appendectomy. Meanwhile, on the second postoperative day, blood culture was positive for *Shigella* species. The postoperative course was uneventful, and the patient was discharged home on the fourth postoperative day, totally asymptomatic.

## DISCUSSION

Shigellosis and its complications are a major cause of morbidity and mortality related to diarrheal diseases in developing countries, probably due to poverty and poor sanitation (4). In 2000, Miron *et al* reviewed the published reports, over a period of 40 years, of 57 children who suffered from intestinal complications of Shigellosis. They identified several surgical complications: intestinal obstruction (53%), appendicitis (28%), colonic perforation (17%) and intra-abdominal abscesses (2%). Most of the cases occurred in developed countries, and many of these children died despite adequate treatment (5,6). Other possible intestinal complications of Shigellosis were toxic mega colon without perforation and proctitis or rectal

prolapse. Newborn infection accounts for less than 1% of all cases of pediatric shigellosis. The clinical course in neonates is usually smooth, with only low grade fever and mild non-bloody diarrhea. However, complications (intestinal and systemic) occur much more commonly than in older children, and the mortality rate is higher reaching 30 to 40% in some developing countries (7). Intestinal perforation is an extremely rare complication of Shigellosis, reported almost exclusively in infants and severely malnourished children. Usually, it is associated with infection due to *Shigella dysenteriae* 1 or *Shigella flexneri* (8). The colon was involved in almost all the cases published in the literature. This may be explained by the pathogenesis of the infection which involves the invasion of colonic mucosal cells by the bacteria, inducing an inflammatory response and leading to the death of epithelial cells with formation of colonic ulcerations, and ultimately potential perforation (9, 10). We presented here the case of a healthy 5-year old child who developed a small intestinal perforation secondary to *Shigella* infection, which is extremely uncommon taking into consideration the age of the patient and the location of the perforation. It might be the extension of a small intestinal mucosal ulceration that caused the perforation; or could be the result of a diffuse vasculitis leading to gut wall necrosis. In fact, autopsy studies done during an epidemic of Shigellosis in Central America revealed deposits of fibrin thrombi in arterioles and veins of submucosa and lamina propria (11), which may have led to ischemia, necrosis and subsequent perforation. Early diagnosis and early initiation of treatment remain definitely the best strategy to prevent intestinal perforation in a patient with Shigellosis.

## CONCLUSION

Small intestinal perforation secondary to *Shigella* infection is extremely uncommon, especially beyond infancy. However, pediatricians should remain alert to the risk of complications of Shigellosis, despite their rarity, and whatever is the age of the patient, because of the significant morbidity and mortality that may be associated with a delayed diagnosis. Researchers and further studies are needed to understand the mechanism underlying small intestinal perforation in the setting of *Shigella* infection in the pediatric age group.

## REFERENCES

1. American Academy of Pediatrics. Red Book: Report of the Committee on Infectious Diseases, 30<sup>th</sup> edition 2015.
2. Holmes LC. *Shigella*. Pediatrics in Review, June 2014, Volume 35, Issue 6.

3. Magill AJ, Hill DR, Solomon T, Ryan ET. Shigellosis. Hunter's Tropical Medicine and Emerging Infectious Disease, 9<sup>th</sup> edition. Elsevier 2013, p 457.
4. Bowen A et al. Importation and Domestic Transmission of Shigella Sonnei resistant to Ciprofloxacin. Morbidity and Mortality Weekly Report. CDC April 2015 / 64(12); 318 – 320.
5. Sochetnick I, Yardeni D, Kowar B, et al. Surgical complications of shigellosis in children. Pediatric Infect Dis J 2000; 19: 898-900.
6. Ashkenazi S. Shigella infections in children: new insights. Seminars in Pediatric Infectious Diseases 2004; 15: 246-252.
7. Wilson CB, Nizet V, Maldonado YA, Remington JS, Klein JO. Microorganisms responsible for neonatal diarrhea. Remington and Klein's Infectious Diseases of the Fetus and Newborn Infant, 8<sup>th</sup> edition. Elsevier 2016, p 369.
8. Lee MS, Koo S, Jeong DG, Tesh VL. Shiga Toxins as Multi-Functional Proteins: Induction of Host Cellular Stress Responses, Role in Pathogenesis and Therapeutic Applications. Toxins 2016 Mar 17; 8(3).
9. Rubin R, Strayer DS. Enteropathogenic Bacterial Infections. Rubin's Pathology 6<sup>th</sup> edition. LWW 2012; p. 360.
10. Perdomo JJ, Gounon P, Sansonetti PJ. Polymorphonuclear leukocyte transmigration promotes invasion of colonic epithelial monolayer by Shigella flexneri. J Clin Invest 1994; 93:633.
11. Hamadani JD, Azad MT, Chowdhury JJ, Kabir I. Intestinal perforation in a child with Shigella dysenteriae type 1 infection: a rare complication. Journal of Diarrhoeal Diseases Research. September 1994; Volume 12 Number 3.

